



Available online at
ScienceDirect
www.sciencedirect.com

Elsevier Masson France
EM|consulte
www.em-consulte.com/en



Review article

Management of traumatic meniscal tear and degenerative meniscal lesions. Save the meniscus



P. Beaufils*, N. Pujol

Service d'orthopédie traumatologie, centre hospitalier de Versailles, 177, rue de Versailles, 78150 Le Chesnay, France

ARTICLE INFO

Article history:

Received 2 July 2017

Accepted 23 August 2017

Keywords:

Meniscus
 Anterior cruciate ligament
 Ramp lesions
 Root tears
 Degenerative meniscus lesion
 Meniscus repair
 Nonoperative treatment
 Meniscectomy
 Consensus

ABSTRACT

Meniscectomy remains one of the most frequent orthopedic procedures, despite meniscal sparing having been advocated for several decades now. Incidence is excessive in the light of scientifically robust studies demonstrating the interest of meniscal repair or of nonoperative treatment for traumatic tear and of nonoperative treatment for degenerative meniscal lesions. It is high time that the paradigm shifted, in favor of meniscal preservation. In traumatic tear, and most particularly longitudinal vertical tear in vascularized zones, repair shows a high success rates in terms of recovery time, functional outcome and cartilage protection. Leaving the meniscus alone may be an option in asymptomatic lesions of the lateral meniscus during anterior cruciate ligament (ACL) reconstruction. Posterior ramp lesions (in associated ACL tear), traumatic root tears and radial lesions are also excellent indications for repair, although it has to be borne in mind that the natural history of these lesions is not completely understood and non-operative treatment also may be considered. Degenerative meniscal lesions are frequently revealed by MRI in middle-aged or elderly subjects. They are closely related to tissue aging and thus probably to osteoarthritic processes. Meniscectomy was long considered the treatment of choice. All but 1 of the 8 recent randomized studies reported non-superiority of arthroscopy over nonoperative treatment, which should thus be the first-line choice, with arthroscopic meniscectomy reserved for cases of failure, or earlier in case of "considerable" mechanical symptoms. Horizontal cleavage in young athletes is a particular case, requiring meniscal repair, to avoid a meniscectomy, which would inevitably be extensive in a young active patient. More than ever, the take-home message is: save the meniscus!

© 2017 Elsevier Masson SAS. All rights reserved.

1. Introduction

"If it is torn, take it out! Take it all out! Even if you just think it's torn, take it out!": thus Smillie in 1967 [1].

In 50 years, a lot has changed, with improvement in knowledge, techniques (most especially, arthroscopy) and the assessment of results.

Basic research has demonstrated the key role of the meniscus in the homeostasis of the knee. It has also shown that certain lesions are able to heal and thus can be repaired [2].

New diagnostic tools have been introduced: MRI and arthroscopy have improved our understanding of meniscal lesions. It is no longer enough just to say that a meniscus is damaged: these new tools determine lesion aspect, extension and exact location and associated lesions, notably of the anterior cruciate ligament (ACL) or cartilage. There is not one but several types of meniscal

lesion and a primary distinction is between traumatic meniscal lesions or, rather, tears, which are true fractures if we compare the meniscus to bone and degenerative meniscal lesions: management is completely different.

Arthroscopy is not just another tool. Its introduction has revolutionized diagnostic assessment and enabled minimally invasive techniques to be developed, with consequent reductions in morbidity and hospital stay.

It remains, however, necessary to assess results, to orient indications and avoid inappropriate treatment.

It is, for example, well known that meniscectomy is frequent, and likely too frequent, worldwide [3,4], not least in France. Arthroscopic meniscectomy is still one of the most common orthopaedic procedures.

In stable knees, subjective results are admittedly good at 10 years: 85% of patients consider their knee normal or nearly normal [5], especially with respect to the medial meniscus. In the lateral meniscus, on the other hand, results rapidly deteriorate, with clear impairment of sports activities [5]. Repeat arthroscopy rates are 6% in the medial and 14% in the lateral meniscus [5].

* Corresponding author.

E-mail address: pbeaufils@ch-versailles.fr (P. Beaufils).

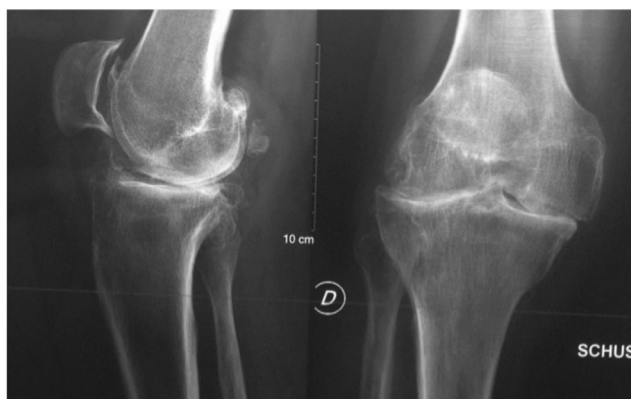

Fig. 1. Generalized osteoarthritis 24 years after medial + lateral meniscectomy on stable knee.

Lateral meniscectomy also incurs a risk of a very severe complication: rapid chondrolysis, usually in young athletes [6,7]. This is characterized by effusion and persistent pain; early Schuss or semiflexed weight bearing radiographs show significant joint line narrowing. Interruption of sport, possible corticosteroid injections and arthroscopic lavage in case of persistent effusion usually achieve a dry knee, but at the cost of major cartilage damage. Osteoarthritis is common following meniscectomy. In a multicenter study by the French Arthroscopy Society, the prevalence of joint line narrowing was 22% in the medial meniscus and 40% in the lateral meniscus at a mean 13 years' follow-up (Fig. 1) [5]. Hulet et al. [8], at 20 years' follow-up, found 56% osteoarthritis following lateral meniscectomy. As well as medial versus lateral side, prognostic factors comprise: resection amount, age at surgery and cartilage status. The latter two factors explain how Osti et al. [9] reported 100% excellent or good results after meniscectomy for longitudinal vertical tear, compared to 79% for complex lesions. Matsusue and Thomson [10] reported 74% excellent results in traumatic lesions, compared to 64% in degenerative lesions.

In unstable knees (ACL tear), isolated meniscectomy is associated with 100% osteoarthritis at 30 years [11]. Meniscectomy associated to ACL reconstruction is a factor for progression toward osteoarthritis. In a multicenter study, Hulet and Graveleau (in Cantin et al.) [12] reported a 10-year osteoarthritis rate of 31% with medial meniscectomy, versus 11% when the meniscus was intact or repaired or in case of abstention; by 20 years, the rates had increased to 46% and 17%, respectively. Multivariate analysis revealed meniscectomy as the main factor, followed by cartilage status, residual laxity and age at surgery.

It was to curb this unfavorable progression that the concept of meniscus sparing gradually developed over the years [13,14]: “Save the meniscus!” Preservation consists in:

- repair;
- or abstention, as a meniscal lesion does not inevitably require meniscal repair.

However, meniscus sparing runs up against a certain resistance in daily practice. There is a curious gap between the conclusions drawn from robust scientific studies in favor of conservation on the one hand and actual practice on the other. There are several reasons for this:

- the myth: “This is what I've always done. It works. Why change?” [15];
- continuous training is insufficient and the learning curve can be off-putting: repair is reputed to be more difficult than meniscectomy. But is that true?

- social pressure: “My MRI scan shows a meniscal lesion, and ‘they’ say it should be removed”, or “My coach says I'll be back on the field faster with a meniscectomy”;
- and, last but not least, health-economic factors related to health insurance systems.

The objectives of this review are to present the possibilities for meniscus sparing in adults, excluding congenital lesions and distinguishing between traumatic lesions (tears) and degenerative lesions.

2. Meniscal preservation

2.1. Traumatic tears

2.1.1. Longitudinal vertical tear

The typical case is of longitudinal vertical tear, with greater or lesser extension; but radial tears, some flaps and posterolateral root tears also come under this heading.

There are two essential criteria:

- meniscal stability or instability, assessed by hook traction, and directly related to lesion extension;
- lesion location, particularly in terms of vascularized or non-vascularized zone, on which healing depends.

2.1.1.1. *We shall not detail all the fixation techniques here.* All-inside, inside-out and outside-in techniques are all effective and indications are basically cultural: for example, use of hybrid material in Europe (Fig. 2) and suture in Korea [16]. What is important is to be eclectic, according to lesion type and to achieve solid fixation with sutures every 7 mm.

The healing process depends on debridement or abrasion of the walls of the tear, especially in chronic lesions. Pujol et al. [17] indirectly demonstrated the major role of abrasion: the rate of meniscal healing on CT-arthroscopy correlated with the reduction in meniscal width (mean, 15%), which may be thanks to generous abrasion. Other experimental and clinical studies [18,19] also showed the interest of abrasion. So, let freshening stand as the first step toward successful meniscal repair!

2.1.1.2. *Results for repair of longitudinal lesions (with or without ACL tear) are good.* Meniscal repair shows results that are comparable to or better than those of meniscectomy [20–22]. Thus:

- time to return to sport and muscular recover is comparable and no longer an argument for meniscectomy;
- functional results are similar, although surgical revision rates are slightly higher with repair;
- functional results are enduring, as seen from 10-year studies [23,24];
- repair provides long-term cartilage protection, on radiography [23] or MRI [25]; the rate of extrusion of the repaired meniscus is low. Having said this, MRI assessment of meniscal repair progression is made uncertain by persistent signal abnormalities [26];
- failure rates are acceptable (6–28%) [27].

Anteroposterior location is not a prognostic factor, but lesion extension may well be [27–29]. Even so, extension should not in itself be a contraindication: one should be prepared to “take the risk of failure”, as any secondary resection will be no greater than the amount of meniscus initially removed [30].

Time to surgery is probably a factor and early repair is probably preferable: acute-stage repair shows better prognosis than chronic

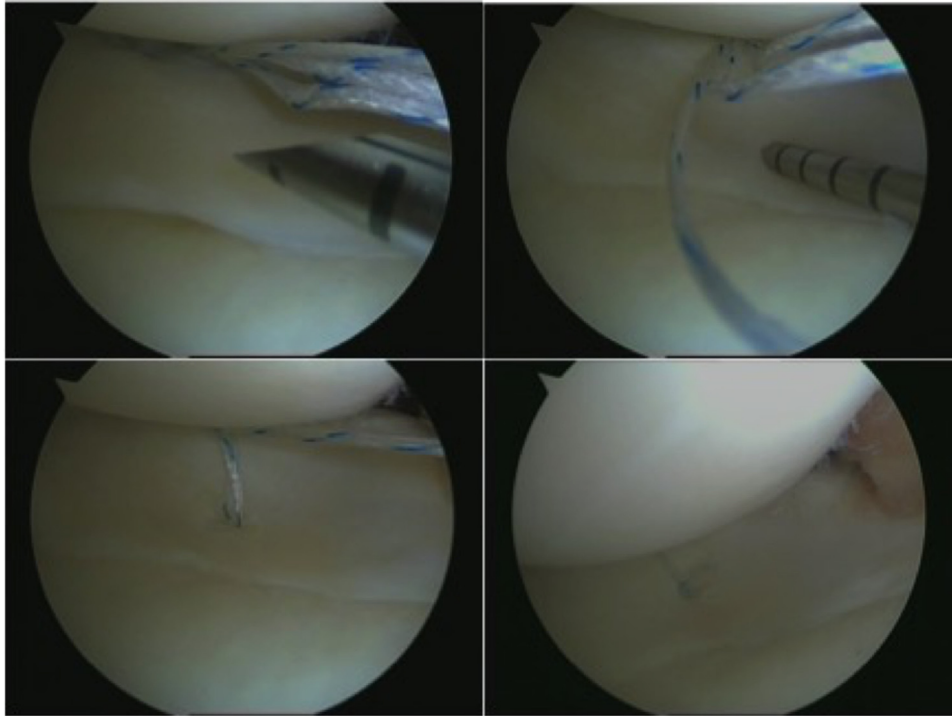


Fig. 2. Longitudinal vertical lesion repaired with FasTFix hybrid material (Smith & Nephew, Andover, MA, USA).

repair [23]. Even so, chronic tear is not in itself a contraindication and one should still “take the risk of failure”.

Age is not in itself a factor of poor prognosis [14,16]. High BMI has also been said to be a factor of poor result [29].

2.1.1.3. Meniscus and ACL. Associated meniscal and ACL tear deserves special consideration. The rate of associated meniscal tear is particularly high [31,32] and increases over time: up to 80% for the medial meniscus at 10 years, while it does not change for the lateral meniscus. Ligament reconstruction seems to protect the meniscus and the meniscus protects the reconstruction.

Meniscal repair is thus strongly indicated here, even in case of bilateral repair [33].

Abstention in meniscal tear is, however, an alternative, recommended as far back as 1992 as an alternative to meniscectomy [34] in stable lesions.

Leaving the meniscus alone without any meniscal procedure during ACL reconstruction is an alternative to repair. Pujol et al. [35], in a systematic review including 15 studies, found failure rates of 0–1.5% for small (< 1 cm) lateral tears (Fig. 3), 0–7% for longer lateral tears, and > 15% for medial tears. It should be stressed, however, that lesion instability was not clearly defined. However, it is safe to say that indications for repair can be extended to the medial meniscus and that abstention has its place for stable lesions of the lateral meniscus [35,36]. But does this mean that all medial tears should be repaired? Such is certainly the current trend; but the present attitude of early ACL reconstruction, with early MRI and surgery as soon as possible, entails frequent discovery of medial meniscus tears, and especially of posterior meniscosynovial ramp lesions [37] (Fig. 4). Repair is generally proposed, by hook on a posterior approach, and it is true that morbidity is low and efficacy good. But does that mean it is necessary? The point is worth discussing: Liu et al. [38], in a recent prospective randomized study, showed that, in stable lesions, results were comparable between repair and simple trephination-abrasion. At all events, if repair is decided on

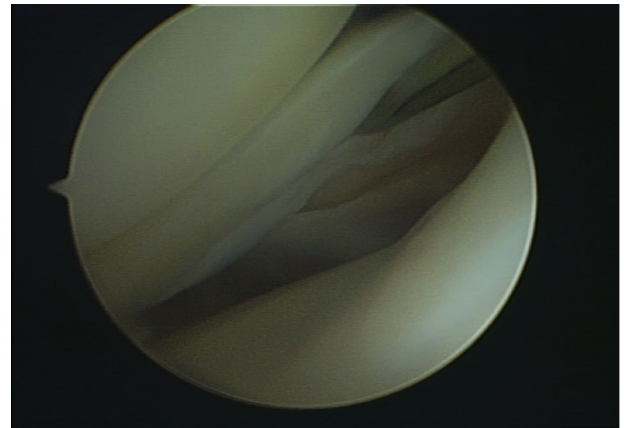


Fig. 3. Vertical lesion of lateral meniscus, with small extension, associated with ACL tear, left in situ during reconstruction.

in this particular situation, hybrid material is unsuitable and it is hook repair that should be used [37].

2.1.2. Other traumatic tears

Some lesions lead to a break in the peripheral meniscal belt, with extrusion and hence loss of meniscal function. Radial and root tears are typical of this.

2.1.2.1. Radial tears. Radial tears extending to the peripheral vascularized zone and especially the meniscosynovial junction should be repaired, so as to restore peripheral wall continuity [39], whether ACL tear is associated or not. The technique is edge-to-edge suture (Fig. 5). Meniscectomy is indicated only in partial lesions in non-vascularized zones.

2.1.2.2. Root tears. Root lesions tears are not well known and poorly defined: they include true avulsion of the bone insertion but

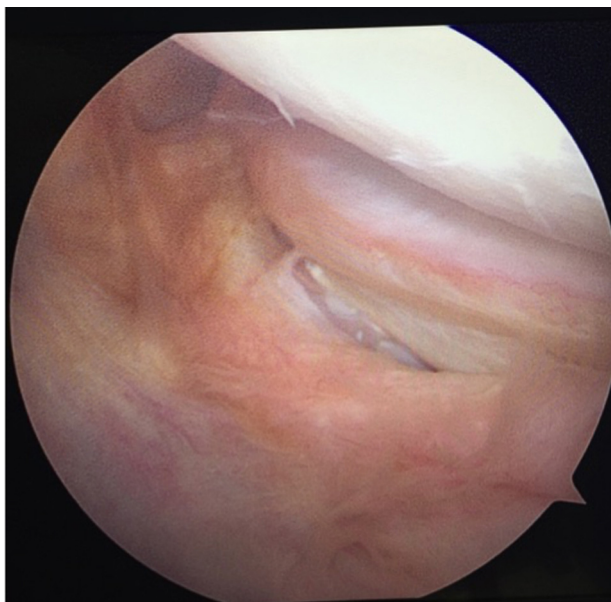


Fig. 4. Posterior meniscosynovial lesion of medial meniscus.

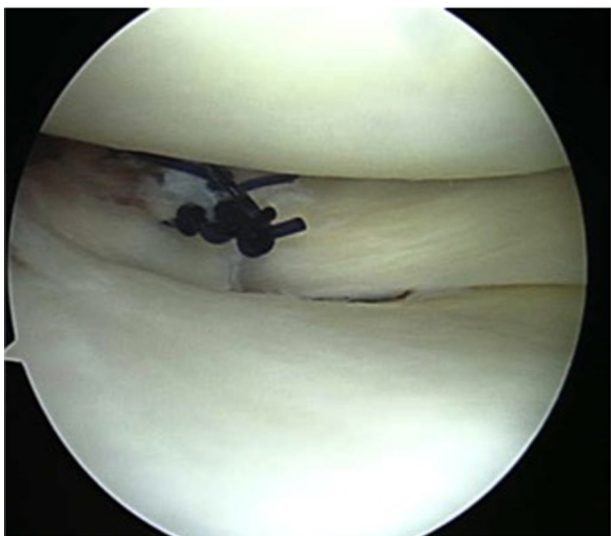


Fig. 5. Radial tear repair.

also, for some authors [40], any radial lesion within a centimeter of the meniscal horn. Reported frequency is thus variable.

Medial lesions are most often degenerative and usually located in the meniscal tissue. Repair has been reported, but efficacy is controversial.

Lateral root tears are traumatic [41] and usually associated with ACL tear [42]. True avulsions are not always immediately visible, and should be explored for by hook palpation, lifting the posterior segment of the lateral meniscus in continuity with the meniscocofemoral ligament.

When the lesion is a few millimeters from the root, repair is as in radial tear.

In true avulsion, transtibial pullout suture is proposed [42,43] (Fig. 6). Outcome is favorable.

2.2. Degenerative meniscal lesions

2.2.1. Horizontal cleavage in young athletes

Horizontal cleavage in young athletes is rare, and can be assimilated to overuse, even though histologic study finds degeneration [44]. It is characterized by intrameniscal (grade 2) or open (grade 3) hypersignal, sometimes associated with synovial cyst; when non-operative management (basically, cessation of sport) fails, surgery may be considered. Meniscectomy would have to be total and has no role in this situation, where the lateral meniscus is often involved. Horizontal lesion orientation and intrameniscal location, precluding freshening, are obstacles to purely arthroscopic repair. We therefore recommend [45] open repair, allowing freshening of the cleavage, working from the peripheral wall, with closure by vertical PDS suture (Fig. 7). Functional results are comparable to repair of vertical lesions. Injection of platelet-rich plasma in the lesion seems to improve functional results and reduce failure rates [46]. Once again, long-term results testify to cartilage protection [47].

2.2.2. Degenerative meniscal lesions in middle-aged subjects

The management of degenerative meniscal lesions in middle-aged and more elderly subjects is a different matter.

Degenerative meniscal lesions show slow progression, in the form of a horizontal cleavage in middle-aged or more elderly subjects (Fig. 8). The most frequent location is in the posterior segment of the medial meniscus.

There is nothing new here! In 1975, Noble and Hambien [48] already showed the high frequency of such lesions in a cadaver study. And Dorfmann et al. published an arthroscopic classification [49], well before MRI became widespread. Thus, degenerative meniscal lesions are common in the general population, whether the knee is symptomatic or not. Prevalence increases with age, reaching 50% in 70 year-olds [50]. It is crucial to bear in mind that 60% of these lesions are asymptomatic and that:

- knee symptoms associated with a degenerative meniscal lesion do not mean that the latter is causing the former;
- and degenerative meniscal lesions do not necessarily mandate aggressive surgery.

The question arises as to the relation between degenerative meniscal lesions and osteoarthritis. Is the degenerative meniscal lesion an early stage of osteoarthritis within the overall aging process? At all events, a degenerative meniscal lesion points to an osteoarthritic knee or at least to elevated risk of osteoarthritis.

Below, we refer to the conclusions of the 2016 ESSKA Meniscus Consensus Project, published in 2017 [51], in which management of degenerative meniscal lesions is again founded on conservative management.

2.2.2.1. *Diagnosis.* Adapted management requires standardized clinical and paraclinical work-up.

What is the role of plain X-ray in the analysis of painful knee in middle-aged or more elderly subjects? In the orthopaedic setting, weight-bearing semi-flexed knee radiographs should be included in the work-up of the middle-aged or older patient with knee pain. Joint line narrowing means advanced osteoarthritis. A skyline patella view is also important for the detection of radiographic evidence of patellofemoral osteoarthritis.

What is the role of knee MRI in the analysis of painful knee in middle-aged or more elderly subjects?

Knee MRI is typically not indicated in the first-line work-up for middle-aged or more elderly subjects with painful knee, but may be requested in selected indications in case of persistent symptoms or severity alarm-signals, or local signs that might suggest

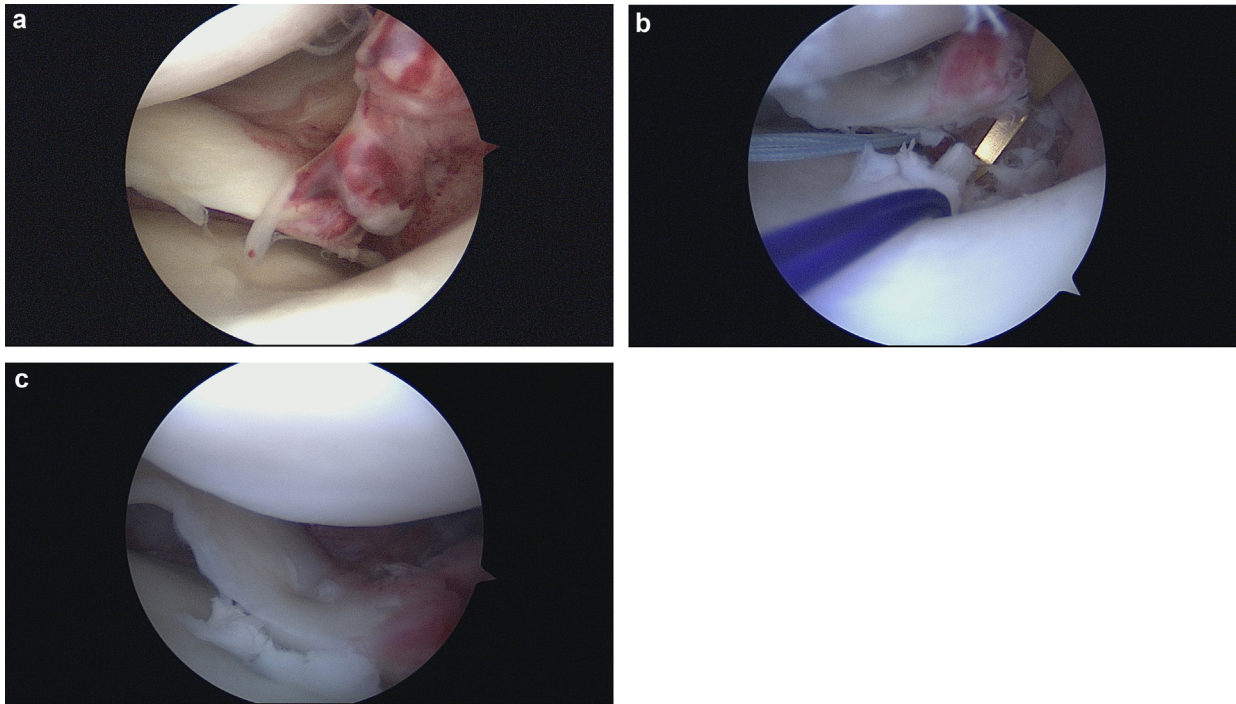


Fig. 6. a: acute traumatic posterior root tear of lateral meniscus; b: non-absorbable braided suture passed through the meniscus by hook; c: transtibial fixation.

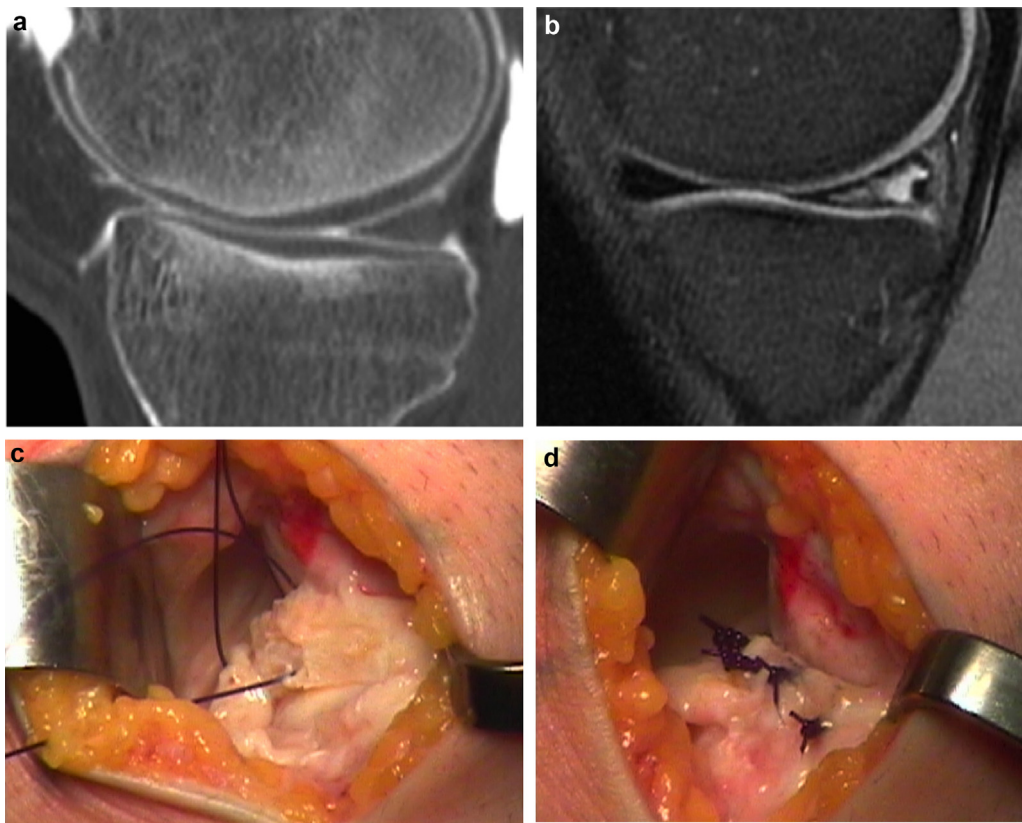


Fig. 7. Horizontal cleavage in young athlete (medial meniscus). a: CT scan and (b) MRI of same knee at same time. CT shows normal meniscus aspect, while MRI shows extensive grade-2 hypersignal; c: open posteromedial repair; cleavage closed by vertical non-absorbable suture (PDS 0, Ethicon); d: final aspect after meniscosynovial junction closure.

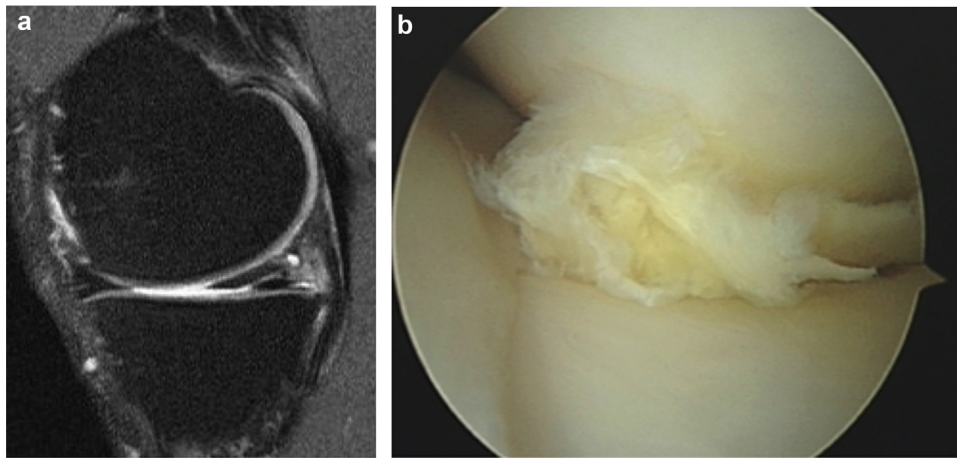


Fig. 8. Degenerative meniscal lesion. a: typical grade-3 medial meniscus aspect on MRI; b: arthroscopic aspect.

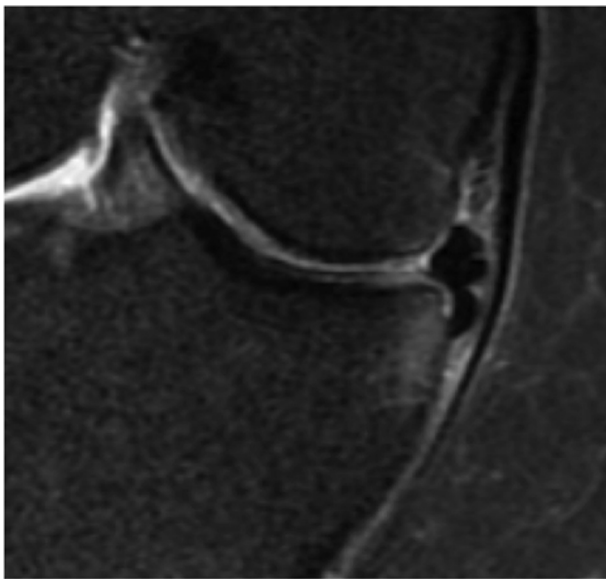


Fig. 9. Degenerative meniscal lesion: flap dislocated in tibial groove.

rarer pathology requiring specific assessment, such as osteonecrosis. Moreover, if history, symptomatology, clinical examination and plain X-ray suggest surgical treatment, knee MRI may usefully identify pathologies matching the symptoms or not, not only determining whether a meniscal lesion exists, but also its location and extension and any flap displacement (Fig. 9). It can also assess early signs of osteoarthritis, such as meniscal extrusion, subchondral edema, etc.

2.2.2.2. Treatment. Arthroscopic meniscectomy to treat degenerative meniscal lesions in middle-aged and more elderly subjects is still far too common. Admittedly, success rates are high [52] and complications rates low (0.27% to 2.8%); but Salzler et al. [53] reported a complications rate of 2.8% and did not consider knee arthroscopy to be a benign procedure.

In contrast, since 2002 and more particularly 2013, several controlled randomized studies compared arthroscopic meniscectomy versus nonoperative management (mainly by physiotherapy) [54–58] or “sham” surgery [59,60]. The older studies, by Moseley et al. [59] and Kirkley et al. [54], concerned osteoarthritic knees and the others knees free of macroscopic osteoarthritis. All except Gouffin et al. [58] concluded that arthroscopic meniscectomy provided

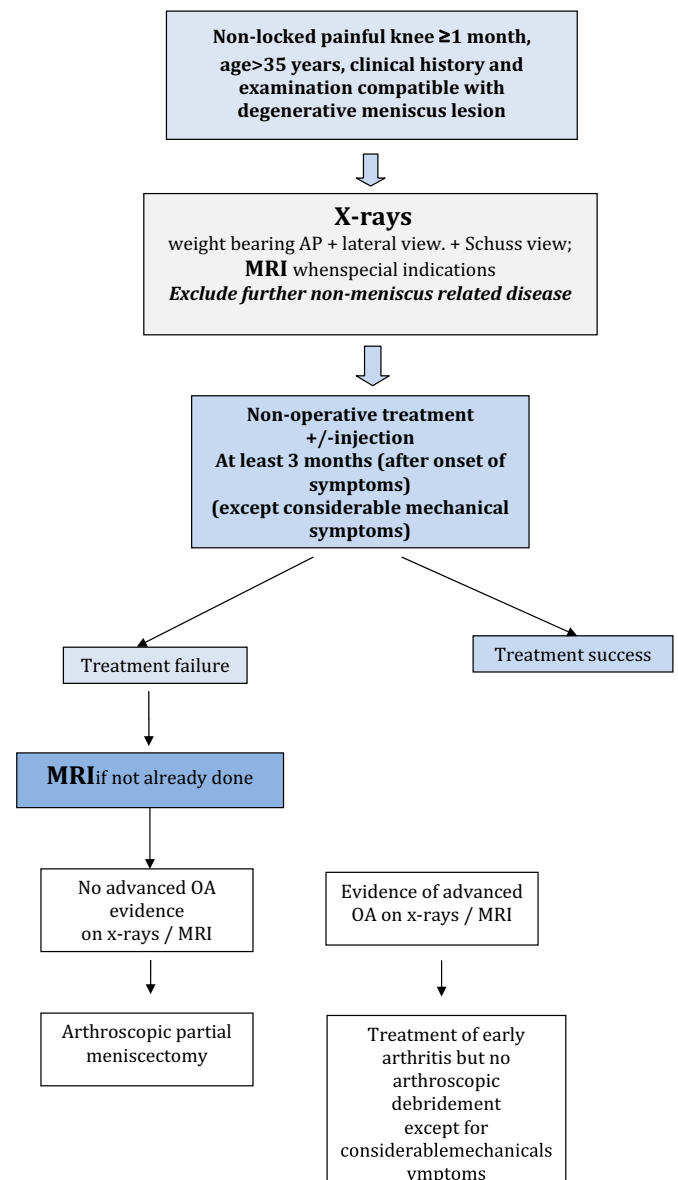


Fig. 10. Degenerative meniscal lesion. ESKA Meniscus Consensus Project decision-tree.

no short- or medium-term benefit over nonoperative treatment, independently of cartilage status. The meta-analysis by Thorlund et al. [61] and Kise's et al. recent study [62] confirmed these findings. However, it should be noted that cross-over for failure of nonoperative treatment in the randomized studies ranged from 0 to 35%, and that all the studies, however well-conducted, involved biases and limitations to which the reader must be alert.

These publications have given rise to wide controversy in the orthopedic community [63,64]. Even so, three messages emerge:

- primary arthroscopic meniscectomy shows no superiority over nonoperative treatment;
- the cross-over rate of 0–35% must be compared to the failure rate of arthroscopic meniscectomy;
- presence of so-called mechanical symptoms does not diminish the results of nonoperative treatment [65]; but “mechanical symptoms” are not well defined and further investigations are needed in this field.

Based on these data, the ESSKA Meniscus Consensus Project [51] developed a decision-algorithm (Fig. 10). In painful knee in middle-aged subjects, plain X-rays should be taken in first line, under the supervision of a locomotor apparatus specialist. MRI is not indicated at this stage, unless a diagnosis requiring complementary examination is suspected. Nonoperative treatment is initiated, comprising physiotherapy and possibly intra-articular injections. Only in case of failure at 3 months is MRI performed, to confirm diagnosis of degenerative meniscal lesion or otherwise, although it is still necessary to check that the lesion matches the symptoms. If radiography and MRI show no signs of advanced osteoarthritis, and notably of meniscal extrusion or facing chondral edema, arthroscopy may be considered. On the other hand, osteoarthritis, when revealed, is to be treated in first line, arthroscopic debridement showing no superiority.

Presence of “considerable” mechanical symptoms constitutes a special case, in which early arthroscopic treatment may be indicated.

3. Conclusion

It is time for a paradigm shift in the management of meniscal tears and lesions [14]. Meniscectomy should no longer be the first-line option. Repair, or sometimes abstention, should whenever feasible be proposed for traumatic tears, and nonoperative treatment for degenerative lesions: i.e., sparing the meniscus.

Inverting the paradigm, however necessary, is not just a matter of robust evidence, which exists but is not enough: education is also required, not only for orthopedic surgeons but equally for the whole care-chain: medical physicians, radiologists, physiotherapists and patients. And all of this depends critically on the health-economic context, which needs to adapt itself to the scientific evidence and not the vice-versa.

Disclosure of interest

P. Beaufils: occasional educational consultant for Zimmer/Biomet and Smith & Nephew. Editor-in-Chief, Orthopaedics and Traumatology: surgery and Research.

N. Pujol: occasional educational consultant for Zimmer/Biomet and Smith & Nephew.

References

- [1] Smillie IS. The current pattern of internal derangements of the knee joint relative to the menisci. *Clin Orthop Relat Res* 1967;51:117–22.
- [2] Arnoczky SP, Warren RF. The microvasculature of the meniscus and its response to injury. An experimental study in the dog. *Am J Sports Med* 1983;11:131–41.
- [3] Agence technique de l'information sur l'hospitalisation (ATI). <http://www.atih.sante.fr/mco/presentation?secteur=MCO>. [Last date accessed Nov 2015].
- [4] Thorlund JB, Hare KB, Lohmander LS. Large increase in arthroscopic meniscus surgery in the middle-aged and older population in Denmark from 2000 to 2011. *Acta Orthop* 2014;85:287–92.
- [5] Chatain F, Adeleine P, Chambat P, Neyret P, Société Française Arthroscopie. A comparative study of medial versus lateral arthroscopic partial meniscectomy on stable knees: 10-year minimum follow-up. *Arthroscopy* 2003;19:842–9.
- [6] Charrois O, Ayrat X, Beaufils P. Rapid chondrolysis after arthroscopic lateral meniscectomy. Report of 4 cases. *Rev Chir Orthopreparatrice Appar Mot* 1998;84:89–92.
- [7] Sonnery Cottet B, Archbold P, Thaunat M, Carneseccchi O, Tostes M, Chambat. Rapid chondrolysis of the knee after partial lateral meniscectomy in professional athletes. *Knee* 2014;21:504–8.
- [8] Hulet C, Menetrey J, Beaufils P, Chambat P, Djian P, Hardy P, et al. Clinical and radiographic results of arthroscopic partial lateral meniscectomies in stable knees with a minimum follow up of 20 years. *Knee Surg Sports Traumatol Arthrosc* 2015;23:225–31.
- [9] Osti L, Liu SH, Raskin A, Merlo F, Bocchi L. Partial lateral meniscectomy in athletes. *Arthroscopy* 1994;10:424–30.
- [10] Matsusue Y, Thomson NL. Arthroscopic partial meniscectomy in patients over 40 years old: a 5 to 11-year follow-up study. *Arthroscopy* 1996;12:39–44.
- [11] Neyret P, Donell ST, Dejour H. Results of partial meniscectomy related to the state of the anterior cruciate ligament. Review at 20 to 35 years. *J Bone Joint Surg Br* 1993;75:36–40.
- [12] Cantin O, Lustig S, Rongieras F, et al. Outcome of cartilage at 12 years of follow-up after anterior cruciate ligament reconstruction. *Orthop Traumatol Surg Res* 2016;102:857–61.
- [13] Beaufils P, Hulet C, Dhénain M, Nizard R, Nourissat G, Pujol N. Clinical practice guidelines for the management of meniscal lesions and isolated lesions of the anterior cruciate ligament of the knee in adults. *Orthop Traumatol Surg Res* 2009;95:437–42.
- [14] Seil R, Becker R. Time for a paradigm change in meniscal repair: save the meniscus! *Knee Surg Sports Traumatol Arthrosc* 2016;24:1421–3.
- [15] Aspenberg P. Myth busting in orthopedics challenges our desire for meaning. *Acta Orthop* 2014;85:547.
- [16] Ahn JH, Lee YS, Yoo JC, Chang MJ, Koh KH, Kim MH. Clinical and second look arthroscopic evaluation of repaired medial meniscus in anterior cruciate ligament reconstructed knees. *Am J Sports Med* 2010;38:472–7.
- [17] Pujol N, Panarella L, Selmi TA, et al. Meniscal healing after meniscal repair: a CT-arthrography assessment. *Am J Sports Med* 2008;36:1489–95.
- [18] Ochi M, Uchio Y, Okuda K, Shu N, Yamaguchi H, Sakai Y. Expression of cytokines after meniscal rasping to promote meniscal healing. *Arthroscopy* 2001;17:724–31.
- [19] Uchio Y, Ochi M, Adachi N, Kawasaki K, Iwasa J. Results of rasping of meniscal tears with and without anterior cruciate ligament injury as evaluated by second-look arthroscopy. *Arthroscopy* 2003;19:463–9.
- [20] Nepple J, Dunn W, Wright R. Meniscal repair outcomes at greater than five years. A systematic literature review and meta-analysis. *J Bone Joint Surg Am* 2012;94:2222–7.
- [21] Paxton ES, Stock MV, Brophy RH. Meniscal repair versus partial meniscectomy: a systematic review comparing reoperation rates and clinical outcomes. *Arthroscopy* 2011;27:1275–88.
- [22] Stein T, Mehling AP, Welsch F, von Eisenhart-Rothe R, Jager A. Long-term outcome after arthroscopic meniscal repair versus arthroscopic partial meniscectomy for traumatic meniscal tears. *Am J Sports Med* 2010;38:1542–8.
- [23] Pujol N, Tardy N, Boisrenoult P, Beaufils P. Long-term outcomes of all-inside meniscal repair. *Knee Surg Sports Traumatol Arthrosc* 2015;23:219–24.
- [24] Lutz C, Dalmay F, Ehkirch FP, Cucurulo T, Laporte C, Le Henaff G, et al. Meniscectomy versus meniscal repair: 10 years radiological and clinical results in vertical lesions in stable knee. *Orthop Traumatol Surg Res* 2015;101:S327–31.
- [25] Dujardin D, Siboni R, Kanagaratnam L, Boisrenoult P, Beaufils P, Pujol N. Long term assessment of meniscal extrusion after meniscal repair. *Orthop Traumatol Surg Res* 2017;103:373–6.
- [26] Pujol N, Tardy N, Boisrenoult P, Beaufils P. Magnetic resonance imaging is not suitable for interpretation of meniscal status ten years after arthroscopic repair. *Int Orthop* 2013;37:2371–6.
- [27] Pujol N, Lorbach O. Meniscal repair results. In: Hulet C, Pereira H, Peretti G, Dientied M, editors. *Surgery of the meniscus*. Berlin Heidelberg: Springer Vg; 2016. p. 343–55.
- [28] Spindler KP, Huston LJ, Wright RW, Kaeding CC, Marx RG, Amendola A, et al. The prognosis and predictors of sports function and activity at minimum 6 years after anterior cruciate ligament reconstruction: a population cohort study. *Am J Sports Med* 2011;39:348–59.
- [29] Laurendon L, Neri T, Farizon F, Philippot R. Prognostic factors for all-inside meniscal repair. A 87-case series. *Orthop Traumatol Surg Res* 2017. <http://dx.doi.org/10.1016/j.otsr.2017.05.025> [Aug 2. pii:S1877-0568(17)30204-9].
- [30] Pujol N, Barbier O, Boisrenoult P, Beaufils P. Amount of meniscal resection after failed meniscal repair. *Am J Sports Med* 2011;39:1648–52.

- [31] Gadeyne S, Besse JL, Galand-Desme S, Lerat JL, Moyen B. Analysis of meniscal lesions accompanying anterior cruciate ligament tears: a retrospective analysis of 156 patients. *Rev Chir Orthop Rep Appar Mot* 2006;92:448–54.
- [32] Yoo JC, Ahn JH, Lee SH, Yoon YC. Increasing incidence of medial meniscal tears in nonoperatively treated anterior cruciate ligament insufficiency patients documented by serial magnetic resonance imaging studies. *Am J Sp Med* 2009;37:1478–83.
- [33] Gonçalves H, Steltzlen C, Boisrenoult P, Beaufils P, Pujol N. High failure rate of anterior cruciate ligament reconstruction with bimeniscal repair: a case-control study. *Orthop Traumatol Surg Res* 2017;103:943–6.
- [34] Beaufils P, Wakim E, Bastos R, Petit Jouvét C. Lésion méniscale dans le cadre des ligamentoplasties antérieures de reconstruction : suture ou abstention. *Rev Chir Orthop* 1992:78.
- [35] Pujol N, Beaufils P. During ACL reconstruction small asymptomatic lesions can be left untreated. A systematic review. *JISAKOS* 2016. <http://dx.doi.org/10.1136/jisakos-2016-000051>.
- [36] Shelbourne KD, Heinrich J. The long-term evaluation of lateral meniscus tears left in situ at the time of anterior cruciate ligament reconstruction. *Arthroscopy* 2004;20:346–51.
- [37] Sonnery-Cottet B, Conteduca J, Thauant M, Gunepin FX, Seil R. Hidden lesions of the posterior horn of the medial meniscus: a systematic arthroscopic exploration of the concealed portion of the knee. *Am J Sports Med* 2014;42:921–6.
- [38] Liu X, Zhang H, Feng H, Hong L, Wang X, Song G. Is it necessary to repair stable ramp lesions of the medial meniscus during anterior cruciate ligament reconstruction? *Am J Sports Med* 2017. <http://dx.doi.org/10.1177/0363546516682493>.
- [39] Ra HJ, Ha JK, Jang SH, Lee DW, Kim JG. Arthroscopic inside-out repair of complete radial tears of the meniscus with a fibrin clot. *Knee Surg Sports Traumatol Arthrosc* 2013;21:26–30.
- [40] Kim SB, Ha JK, Lee SW, Kim DW, Shim JC, Kim JG, et al. Medial meniscus root tear re-fixation: comparison of clinical, radiologic and arthroscopic findings with medial meniscectomy. *Arthroscopy* 2011;27:346–54.
- [41] Ahn JH, Lee YS, Chang JY, Chang MJ, Eun S, Kim SM. Arthroscopic all-inside repair of the lateral meniscus root tear. *Knee* 2009;16:77–80.
- [42] Ahn JH, Lee YS, Yoo JC, Chang MJ, Park SJ, Pae YR. Results of arthroscopic all-inside repair for lateral meniscus root tear in patients undergoing concomitant anterior cruciate ligament reconstruction. *Arthroscopy* 2010;26:67–75.
- [43] Kodama Y, Furumatsu T, Fujii M, Tanaka T, Miyazawa S, Ozaki T. Pullout repair of a medial meniscus posterior root tear using a FasT-Fix® all-inside suture technique. *Orthop Traumatol Surg Res* 2016;102:951–4.
- [44] Meister K, Indelicato P, Spanier S, Franklin J, Batts J. Histology of the torn meniscus. A comparison of histologic differences in meniscal tissue in anterior cruciate ligament-intact and anterior cruciate ligament-deficient knees. *Am J Sp Med* 2004;32:1479–83.
- [45] Pujol N, Bohu Y, Boisrenoult P, Macdes A, Beaufils P. Clinical outcomes of open meniscus repair of horizontal meniscus tears in young patients. *Knee Surg Sports Traumatol Arthrosc* 2013;21:1530–3.
- [46] Pujol N, Salle De Chou E, Boisrenoult P, Beaufils P. Platelet-rich plasma for open meniscal repair in young patients: any benefit? *Knee Surg Sports Traumatol Arthrosc* 2015;23:51–8.
- [47] Sallé de Chou E, Pujol N, Rochcongar G, Cucurulo T, Potel JF, Dalmay F, et al. Analysis of short and long-term results of horizontal meniscal tears in young adults. *Orthop Traumatol Surg Res* 2015;101:S317–22.
- [48] Noble J, Hambien DL. The pathology of the degenerate meniscus lesion. *J Bone Joint Surg Br* 1975;57:180–6.
- [49] Dorfmann H, Juan LH, Bonvarlet JP, Boyer T. Arthroscopy of degenerative lesions of the medial meniscus. Classification and treatment. *Rev Rhum Mal Osteoartic* 1987;54:303–10 [French].
- [50] Englund M, Guermazi A, Gale D, Hunter DJ, Aliabadi P, Clancy M, et al. Incidental meniscal findings on knee MRI in middle-aged and elderly persons. *N Engl J Med* 2008;359:1108–15.
- [51] Beaufils P, Becker R, Kopf S, Englund M, Verdonk R, Ollivier M, et al. Surgical management of degenerative meniscus lesions: the 2016 ESSKA meniscus consensus. *Knee Surg Sports Traumatol Arthrosc* 2017;25:335–46.
- [52] Khan M, Evaniew N, Bedi A, Ayeni OR, Bhandari M. Arthroscopic surgery for degenerative tears of the meniscus: a systematic review and meta-analysis. *CMAJ* 2014;186:1057–64.
- [53] Salzler MJ, Lin A, Miller CD, Herold S, Irrgang JJ, Harner CD. Complications after arthroscopic knee surgery. *Am J Sports Med* 2014;42:292–6.
- [54] Kirkley A, Birmingham TB, Litchfield RB, Giffin JR, Willits KR, Wong CJ, et al. A randomized trial of arthroscopic surgery for osteoarthritis of the knee. *N Engl J Med* 2008;359:1097–107.
- [55] Herrlin SV, Wange PO, Lapidus G, Hällander M, Werner S, Weidenhielm L. Is arthroscopic surgery beneficial in treating non-traumatic, degenerative medial meniscal tears? A five-year follow-up. *Knee Surg Sports Traumatol Arthrosc* 2013;21:358–64.
- [56] Katz JN, Brophy RH, Chaisson CE, et al. Surgery versus physical therapy for a meniscal tear and osteoarthritis. *N Engl J Med* 2013;368:1675–84.
- [57] Yim J-H, Seon J-K, Song E-K, Choi J-I, Kim M-C, Lee K-B, et al. A comparative study of meniscectomy and nonoperative treatment for degenerative horizontal tears of the medial meniscus. *Am J Sports Med* 2013;41:1565–70.
- [58] Gauffin H, Tagesson S, Meunier A, Magnusson H, Kvist J. Knee arthroscopic surgery is beneficial to middle-aged patients with meniscal symptoms: a prospective, randomised, single-blinded study. *Osteoarthr Res Soc* 2014;22:1808–16.
- [59] Moseley JB, O'Malley K, Petersen NJ, Menke TJ, Brody BA, Kuykendall DH, et al. A controlled trial of arthroscopic surgery for osteoarthritis of the knee. *N Engl J Med* 2002;347:81–8.
- [60] Sihvonen R, Paavola M, Malmivaara A, Itälä A, Joukainen A, Nurmi H, et al. Arthroscopic partial meniscectomy versus sham surgery for a degenerative meniscal tear. *N Engl J Med* 2013;369:2515–24.
- [61] Thorlund JB, Juhl CB, Roos EM, Lohmander LS. Arthroscopic surgery for degenerative knee: systematic review and meta-analysis of benefits and harms. *Br Med J* 2015;49:1229–35.
- [62] Kise NJ, Risberg MA, Stensrud S, Ranstam J, Engebretsen L, Roos EM. Exercise therapy versus arthroscopic partial meniscectomy for degenerative meniscal tear in middle aged patients: randomized controlled trial with two-year follow-up. *BMJ* 2016;20:354–74.
- [63] Bollen SR. Is arthroscopy of the knee completely useless? Meta-analysis – a reviewer's nightmare. *Bone Joint J* 2015;97-B:1591–2.
- [64] Elattrache N, Lattermann C, Hannon M, Cole B. New England Journal of Medicine article evaluating the usefulness of meniscectomy is flawed. *Arthroscopy* 2014;30:542–3.
- [65] Sihvonen R, Englund M, Turkiewicz A, Järvinen TLN. Mechanical symptoms and arthroscopic partial meniscectomy in patients with degenerative meniscal tear: a secondary analysis of a randomized trial. *Ann Intern Med* 2016;164:449–55.