



EXHIBIT SELECTION

Reconstruction of the Anterior Cruciate Ligament in the Skeletally Immature Athlete: A Review of Current Concepts

AAOS Exhibit Selection

Peter D. Fabricant, MD, Kristofer J. Jones, MD, Demetris Delos, MD, Frank A. Cordasco, MD, MS, Robert G. Marx, MD, MSc, Andrew D. Pearle, MD, Russell F. Warren, MD, and Daniel W. Green, MD, MS

Investigation performed at the Hospital for Special Surgery, New York, NY

Abstract: Intrasubstance tears of the anterior cruciate ligament (ACL) were once considered a rare injury in skeletally immature athletes but are now observed with increasing frequency. Treatment strategies have evolved as recent studies have identified unique considerations specific to the skeletally immature patient. The current literature now supports the trend toward early operative treatment to restore knee stability and prevent progressive meniscal and/or articular cartilage damage, but the optimal approach to ACL reconstruction in this age group remains controversial. Despite the reported clinical success of transphyseal reconstruction, iatrogenic growth disturbance secondary to physeal damage remains a genuine concern. The reluctance to place drill-holes across open physes has led to the development of numerous “physeal-sparing” reconstruction techniques using anatomic femoral and tibial footprints that have adequately restored anteroposterior and rotational knee stability in biomechanical studies but have demonstrated mixed results in the clinical setting. The intent of this review is to (1) highlight the unique anatomic considerations pertaining to ACL reconstruction in the skeletally immature athlete, (2) discuss preoperative clinical and radiographic assessment of the pediatric patient with a suspected ACL injury, (3) review transphyseal and physeal-sparing reconstruction techniques and highlight surgical technical considerations, (4) present clinical outcomes according to patient and technique-specific factors, and (5) review age-specific injury prevention treatment strategies and a novel treatment algorithm based on skeletal maturity. ACL reconstruction in the skeletally immature athlete typically results in a successful clinical outcome, yet the optimal surgical technique is still controversial. This review will help guide the management of ACL injuries in the pediatric athlete.

Historically, intrasubstance tears of the anterior cruciate ligament (ACL) were once thought to be rare among pediatric patients. Recently, a dramatic rise in athletic activity along with increased recognition of this condition have led to a commensurate increase in the number of ACL injuries

diagnosed in patients with open physes. Treatment strategies for ACL injuries in skeletally immature patients have evolved; however, there are still no clear management guidelines. Overall, the perceived risk of physeal damage has led to reluctance to routinely use the conventional ACL reconstruction

Disclosure: None of the authors received payments or services, either directly or indirectly (i.e., via his or her institution), from a third party in support of any aspect of this work. One or more of the authors, or his or her institution, has had a financial relationship, in the thirty-six months prior to submission of this work, with an entity in the biomedical arena that could be perceived to influence or have the potential to influence what is written in this work. No author has had any other relationships, or has engaged in any other activities, that could be perceived to influence or have the potential to influence what is written in this work. The complete **Disclosures of Potential Conflicts of Interest** submitted by authors are always provided with the online version of the article.

techniques that have proven successful in adult patients. This article provides a comprehensive review of current concepts pertaining to ACL reconstruction in skeletally immature athletes, including a review of pertinent anatomy, risk factors for ACL injury and associated pathology, unique preoperative considerations for skeletally immature patients, the natural history following nonoperative management and the sequelae of delayed reconstruction, and an overview of currently used techniques and their clinical outcomes. Lastly, an evidence-based surgical treatment algorithm based on skeletal maturity is presented to guide surgical decision-making.

Anatomy of the Pediatric Knee

The ACL develops in utero, appearing at twenty-four weeks of gestation as a confluence of collagen ligament fibers that blend with the periosteum. At thirty-six weeks of gestation, an epiphyseal attachment can be observed, with interdigitation of the ACL collagen fibers with adjacent bone, transitional fibrocartilage, and mineralized fibrocartilage¹. Anatomically, the

ACL comprises two functional and anatomic bundles, the anteromedial and posterolateral bundles (Fig. 1). The anteromedial bundle originates on the femur at the transition between the intercondylar line and the cartilage margin, and it inserts along the medial aspect of the intercondylar eminence. The posterolateral bundle originates at the anteroinferior aspect of the femoral ACL origin, and it inserts just lateral to the central aspect of the intercondylar eminence. The sizes of the anteromedial and posterolateral bundles can vary according to patient height, weight, and body mass index (BMI)².

Pediatric development of the femoral intercondylar notch continues steadily through skeletal development until eleven years of age, after which time there is no significant increase in the width of the anterior portion of the notch (Fig. 2)³. After ten years of age, the width of the notch is greater in boys than in girls. The lateral intercondylar ridge (“resident’s ridge”) is located on the medial aspect of the lateral femoral condyle and marks the anterior border of the femoral ACL footprint with the knee in 90° of flexion. It is important to note

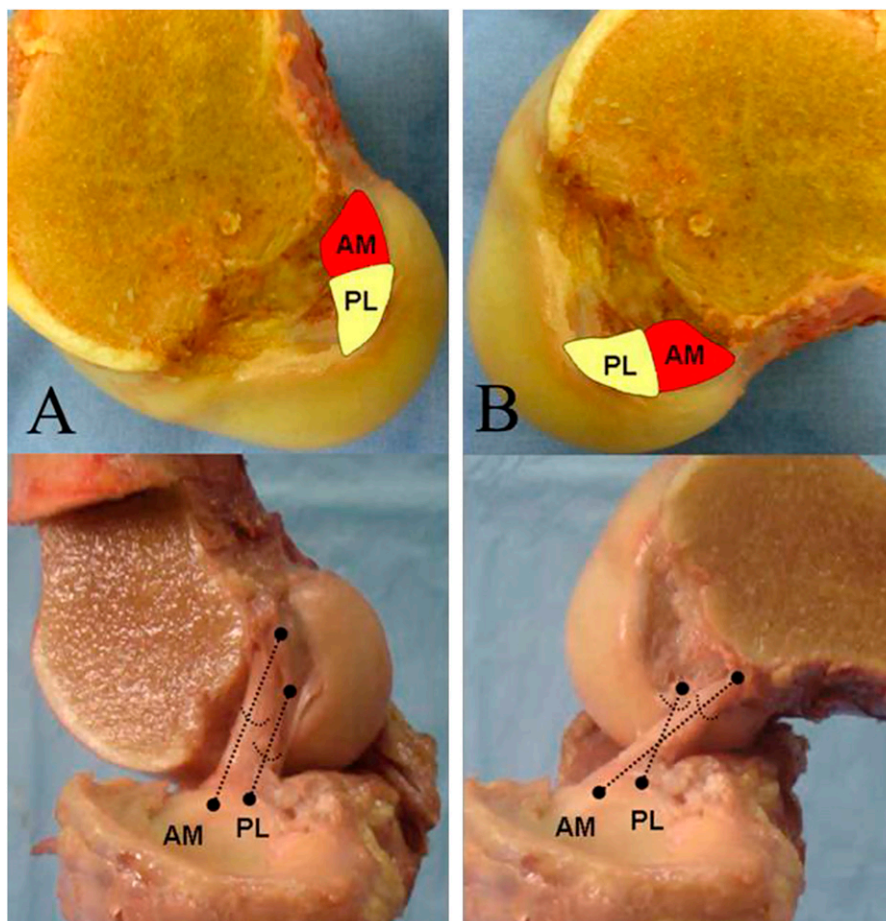


Fig. 1
Functional and anatomic bundles of the ACL. The functional and anatomic bundles of the ACL are illustrated with the medial femoral condyle removed in knee extension (**Fig. 1-A**) and in knee flexion (**Fig. 1-B**). As the knee flexes, the anteromedial (AM) bundle becomes taut as the origin “rolls over” the posterolateral (PL) bundle origin. (Reproduced from: Chhabra A, Starman JS, Ferretti M, Vidal AF, Zantop T, Fu FH. Anatomic, radiographic, biomechanical, and kinematic evaluation of the anterior cruciate ligament and its two functional bundles. *J Bone Joint Surg Am.* 2006 Dec;88 Suppl 4:2:10.)

TABLE I The Hospital for Special Surgery Shorthand Bone Age Assessment Tool*

Age (yr)		Hand Radiograph Finding
Girls	Boys	
10	12.5	Appearance of hook of hamate
11	13	Appearance of MP sesamoid of thumb
NA	13.5	Proximal radial aspect of radial epiphysis has met maximum width of distal radial metaphysis; no capping
12	14	Capping of distal radial epiphysis
13	15	Closure of thumb distal phalanx physis
13.5	15.5	Closure of index finger distal phalanx physis
14	16	Closure of index finger proximal phalanx physis

*MP = metacarpophalangeal, NA = not available, and closure = bridging by >50% bone across physis.

that this landmark is utilized to determine accurate placement of the femoral tunnel position during ACL reconstruction, and several studies have demonstrated that it is present more frequently in older adolescents (88% in thirteen to twenty-year-olds compared with 44% to 63% in three to twelve-year-olds)^{1,4}.

Additional considerations that are unique to the pediatric knee include the anatomy of the tibial and femoral physes. The distal femoral physis contributes 70% of the total femoral length and 37% of the total limb length over the course of skeletal development, at an average rate of 10 mm per year. The distance between the femoral physis and the femoral origin of the ACL remains unchanged from gestation through skeletal maturity and averages approximately 3 mm¹. The proximal tibial physis contributes approximately 55% of the total tibial length and 25% of the total limb length over the course of skeletal development, at a rate of 6.4 mm per year.

Risk Factors for ACL Injury

Characterization of the “at-risk” pediatric athlete involves several internal and external risk factors. Internal risk factors include those intrinsic to the patient, such as mechanical, hormonal, and anatomic considerations. Biomechanical risk factors are introduced with pivoting, deceleration, or landing from a jump and are largely related to posture, alignment, and increased quadriceps activation during these activities. For instance, female athletes are “quadriceps-dominant,” with higher quadriceps/hamstring activation ratios compared with male athletes. This has led to the development of strength and conditioning programs targeted at ACL tear prevention⁵. Several studies have been performed with the goal of finding an association between sex hormone receptors located within the ACL (including those for estrogen^{6,7}, testosterone, and relaxin⁸) and ligament injury. It is possible that these sex hormones alter the mechanical properties of the ACL, but the precise mechanism has not been fully elucidated^{9,10}. Anatomic risk factors include increased anterior pelvic tilt, increased femoral anteversion, increased quadriceps angle, decreased intercondylar

notch width, and increased posterior tibial slope¹¹. These intrinsic risk factors may preferentially predispose girls to increased ACL strain and injury, as female athletes tend to exhibit these anatomic characteristics more frequently than male athletes^{8,11,12}.

External risk factors include variables such as weather conditions, footwear, and footwear-surface interaction. Weather conditions contribute to poor playing surfaces, as low rainfall and high evaporation during summer months may result in harder playing surfaces and increased strain on the ACL. An increased coefficient of friction between the shoe and the playing surface can improve stability and performance, but it may also cause increased strain on the ACL, resulting in higher rates of ACL injury. Likewise, studies have demonstrated that the number, length, and placement of cleats (specifically at the peripheral margin of the lateral sole of the foot) may also increase an athlete’s probability of ACL injury by increasing strain on the ACL^{13,14}.

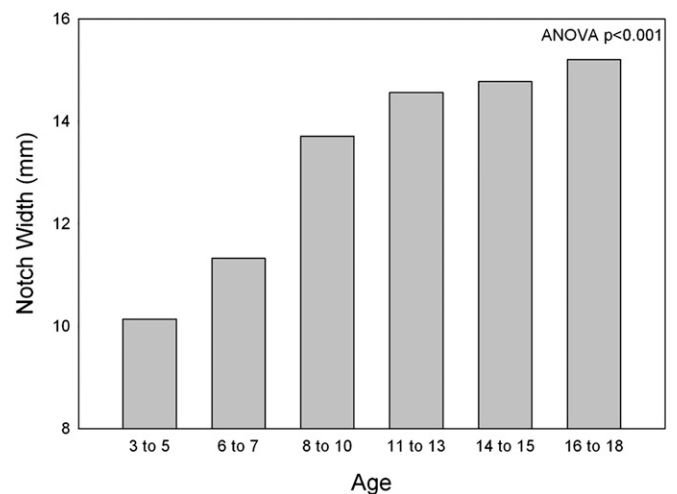


Fig. 2
In pediatric patients, the femoral notch continues to grow until the patient is eleven years of age. ANOVA = analysis of variance.

TABLE II Clinical Outcomes Following Nonoperative Management and Delayed Surgical Reconstruction*

	First Author	Year	No. of Patients	Recurrent Instability	Further Medial Meniscal Injury
Nonoperative management	Graf ²⁷	1992	12	100%	58%
	Mizuta ²⁹	1995	18	NR	NR
	Aichroth ²⁸	2002	23	NR	NR
Early compared with delayed surgery	Millett ³¹	2002	39	NR	11% early, 36% delayed; favors early
	Henry ³⁰	2009	56	NR	16% early, 41% delayed; favors early
	Lawrence ³²	2011	70	NR	22% early, 83% delayed; favors early

*IKDC = International Knee Documentation Committee, NR = not reported, and PF = patellofemoral.

Associated Intra-Articular Pathology

Meniscal Tears

Similar to the situation in adults, several studies have demonstrated that pediatric patients who undergo simultaneous meniscal repair at the time of ACL reconstruction have a significantly higher meniscal healing rate compared with patients who undergo meniscal repairs alone. Krych et al. reported healing rates of approximately 74% for all tear patterns and 84% for simple tears (those with one major tear component: vertical, longitudinal, horizontal, or radial) in patients less than eighteen years of age at eight years of follow-up. Complex tear patterns (a multiple-plane

combination of two or more tear components) as well as bucket-handle tears had significantly lower healing rates of approximately 60% at two years¹⁵. Repairs of the medial meniscus also had a higher rate of failure compared with repairs of the lateral meniscus. Although patients with open physes at the time of surgery showed an increased rate of failure, this was potentially due to decreased compliance with postoperative protocols.

Combined Ligamentous Injuries

Similar to the situation in adults, recent data support delayed ACL reconstruction with nonoperative management of grade-

TABLE III Recommended Rehabilitation Protocol Following All-Epiphyseal Reconstruction*

Phase	Time† (wk)	Range of Motion	Strength	Activity	Other
1	0 to 4	Full extension 90° flexion Patellar mobility	Quad. contraction	Home exercise program	
2	4 to 8	0° to 125°	Single leg stance with neuromuscular control	Normalize WBAT gait	
3	8 to 16	Full range of motion	Quad. strengthening Core strengthening Eccentric quad. control		
4	16 to 20	Maximize flexibility	Maximize strength	Demonstrate athletic-ready position stance	HSS ACL injury prevention assessment
5	20 to 28	Maximize flexibility	Dynamic control with jumping and landing	Symptom-free running Independent gym program	
6	28 to return to sport	Maximize flexibility	Hop test >85% of unaffected limb Dynamic control with sport-specific movements	Lack of apprehension with sport-specific movements	Patient/parent compliance with functional bracing

*WBAT = weight-bearing as tolerated, and HSS = Hospital for Special Surgery. †Time is approximate. Rehabilitation program progression is dependent on the patient's ability to fulfill goals at each phase.

TABLE II (continued)

Degenerative Changes	Return to Previous Level of Activity or Better	Lysholm Score	Tegner Score	IKDC Score
NR	NR	NR	NR	NR
61%	5.5%	64.3	NR	NR
43.5%	NR	52.4	4.2	NR
NR	NR	NR	NR	NR
NR	89.6% early, 65.4% delayed; favors early	NR	NR	94.6 early, 82.4 delayed; favors early
Lateral compartment and PF changes greater in delayed group	NR	NR	NR	NR

II and III tears of the medial collateral ligament (MCL) in skeletally immature patients. In these cases, treatment with a hinged knee brace until surgical ACL reconstruction is appropriate. In a cohort of patients (mean age, 15.6 years; range, fourteen to seventeen years) with combined MCL and ACL injuries, the mean delay to ACL reconstruction in patients with successful outcomes was thirty-three days and reconstruction resulted in a reported mean Lysholm score of 96, with 100% returning to athletic activity¹⁶.

Chondral Lesions

Traumatic chondral lesions have been observed in up to one-half of high school athletes with ACL injuries¹⁷. There is a higher prevalence of combined ACL and articular cartilage injuries in young female athletes compared with male athletes. Many studies have demonstrated a positive effect of younger age on the outcome of cartilage repair techniques such as microfracture or osteochondral autograft transfer (OAT) for acute traumatic cartilage injury¹⁸. Currently there is limited information on the effect of ACL reconstruction on simultaneous articular cartilage repair.

Evaluation of the Pediatric Athlete

Children presenting with an ACL tear often report a sudden varus or valgus force along with a twisting at the knee associated with an audible or palpable “popping” sensation. Initial examination of the patient should rule out concomitant musculoskeletal injuries. Examination of the knee should include inspection for acute hemarthrosis, which is helpful in determining the severity of the injury. ACL injuries can be present in up to 65% of adolescents presenting with acute traumatic hemarthrosis¹⁹. Reliable physical examination maneuvers to detect ACL insufficiency include the Lachman test, the anterior drawer test with the knee in 90° of flexion, and the pivot-shift test. Pain and swelling can affect patient compliance and thus the accuracy of these tests. The pivot-shift test is positive in 98% of anesthetized patients with ACL insufficiency compared with only 35% of patients who are awake during the examination¹⁹. In addition to checking for clinical malalignment, it is important to evaluate the patient for preoperative limb-length discrepancy. Clinical malalignment and limb-length discrepancy are checked preoperatively to reveal any baseline irregularities and/or side-to-side differences. As the

patient is followed through skeletal maturity, baseline measurements allow the surgeon to determine if any postoperative differences existed preoperatively or if they were possibly caused by the surgery and should be addressed. Limb-length discrepancy is typically measured with a tape measure (from the anterior superior iliac spine to the medial malleolus) or by placing blocks under the clinically shorter limb to correct any pelvic obliquity that may be present.

Imaging

Magnetic resonance imaging (MRI) is 95% sensitive and 88% specific for detecting ACL tears in children. The primary signs of ACL rupture on MRI include an abnormal ligament course, abnormal signal intensity such as diffusely increased signal on intermediate or T2-weighted images, and ligament discontinuity²⁰. In addition to the standard radiographic evaluation performed in adults, we additionally obtain fifty-one-inch standing (130-cm) anteroposterior hip-to-ankle radiographs (Fig. 3). This allows for accurate preoperative assessment of subtle limb-length discrepancy and angular deformity. Skeletal maturity is traditionally assessed with use of a posteroanterior radiograph of the left hand, with reference to the Greulich and Pyle atlas^{21,22}. This method uses a predictable pattern of ossification in the wrist to accurately estimate skeletal age. At our institution, the Hospital for Special Surgery (HSS) short-hand bone age assessment tool facilitates evaluation of bone age without the use of an atlas. This system relies on recognition and memorization of only a few key radiographic findings (Table I), and it has been validated and shown to have equivalent accuracy compared with the Greulich and Pyle method²³. With these additional radiographs, a growth chart may be used to predict limb-length discrepancy at skeletal maturity.

Natural History of the Disease

Although nonoperative management is an appealing option given the increased healing potential of children and the risk of physeal damage with surgical reconstruction, clinical results following nonoperative management have not been favorable. Partial ACL injuries represent one-quarter to one-half of the midsubstance ACL tears that occur in children. Although children tend to have better healing capacity than adults, animal studies have demonstrated mixed results regarding the

precise healing potential after partial ACL transection²⁴. Kocher et al. showed that approximately one-third of children (mean age, 13.7 years) with a partial ACL tear who were treated nonoperatively with a hinged knee brace, partial weight-bearing for six to eight weeks, and a progressive ACL rehabilitation protocol ultimately required surgical reconstruction for persistent instability²⁵. The authors noted several risk factors for failure of nonoperative management and developed an algorithm for acute treatment. Overall, they recommended surgical management for patients with a tear greater than one-half of the thickness of the ACL, a tear of the posterolateral bundle, a pivot-shift examination result of grade B or greater, or a skeletal age of more than fourteen years.

Nonoperative management of a complete ACL rupture generally leads to a poor outcome. Additionally, it is associated with a high rate of sport dropout because of recurrent instability, as studies have demonstrated that up to 50% of children treated nonoperatively do not return to athletic activity²⁶. Progressive instability can result in progressive meniscal and articular cartilage damage as well as Fairbanks changes (e.g., condylar squaring and joint space narrowing on an anteroposterior radiograph) in 61% of knees²⁷⁻²⁹. Instability and

cartilage degeneration are typically observed in patients who do not modify their post-injury activity level, as is often the case in active children and adolescents.

There has been considerable debate in the literature regarding the optimal time to perform ACL reconstruction in skeletally immature patients. Concerns regarding physeal damage, growth arrest, and subsequent sequelae including angular deformity and limb-length discrepancy have led some surgeons to delay surgical management until skeletal maturity. Delayed reconstruction, however, has its own important drawbacks including the possible development of progressive intra-articular pathology³⁰⁻³². Table II highlights clinical outcomes following nonoperative management and delayed surgical reconstruction. These poor results have resulted in the development of modern operative techniques for pediatric ACL reconstruction.

Modern Operative Techniques

Iliotibial Band Reconstruction: Extraphyseal Reconstruction

Iliotibial band reconstruction (the modified McIntosh procedure) was popularized by Kocher et al.³³. It is a physeal-sparing reconstruction with combined intra-articular and extra-articular stabilization. This procedure is primarily indicated for patients at Tanner stage I or II. In this procedure, the central one-third of the iliotibial band is harvested proximally and left attached to the Gerdy tubercle distally. The graft is brought through the knee in an over-the-top-position posteriorly and passed under the intrameniscal ligament anteriorly on the tibia. The graft is fixed with suture to the intermuscular septum and periosteum on the femoral side and to the periosteum on the tibial side (Fig. 4-A). Clinical outcomes following this procedure have been favorable; a long-term study by Kocher et al. demonstrated a mean IKDC (International Knee Documentation Committee) score of 96.7, a mean Lysholm score of 95.7, a failure rate of 4.5% (two patients, at five and eight years postoperatively), and no reported instances of growth disturbance³³.

Transphyseal Reconstruction

Both partial transphyseal and complete transphyseal reconstruction techniques have been reported. Partial transphyseal reconstruction includes sparing of either the tibial or the femoral physis, with transphyseal stabilization on the opposite side. This procedure has been used for patients at Tanner stages I through V. Although the graft source is selected largely on the basis of surgeon preference, autologous hamstring is preferred. Autologous tendon with bone plugs (e.g., bone-patellar tendon-bone autograft) may induce local growth arrest if placed across the physis. Furthermore, injury to the apophysis of the anterior tibial tubercle during patellar tendon harvesting may cause a tibial recurvatum deformity with premature arrest of the anterior proximal tibial physis. Tunnel size, tunnel inclination, and drilling technique (transtibial compared with anteromedial) are factors that may influence the volume percentage of the distal femoral physis that is disrupted and thus the risk of physeal damage³⁴. Graft fixation is also based on surgeon preference. Outcomes from transphyseal reconstruction have

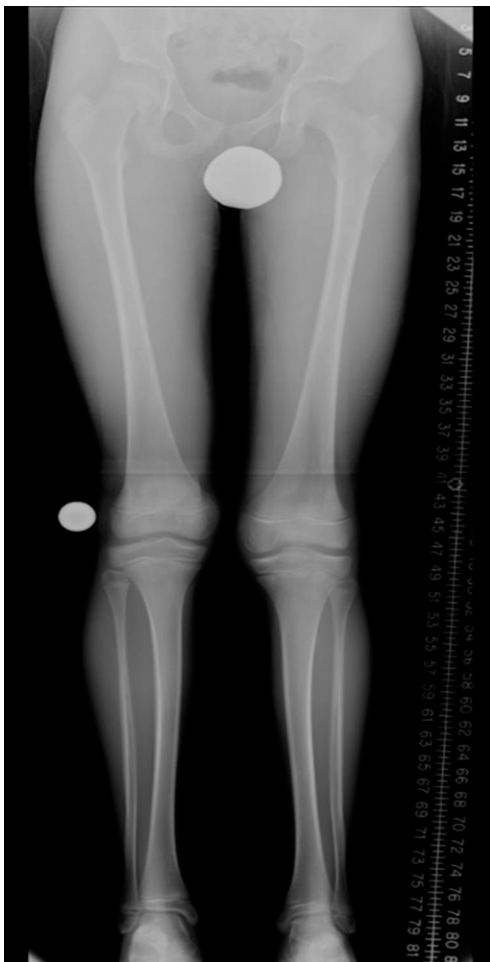

Fig. 3
Representative standing 51-in (130-cm) hip-to-ankle radiograph.

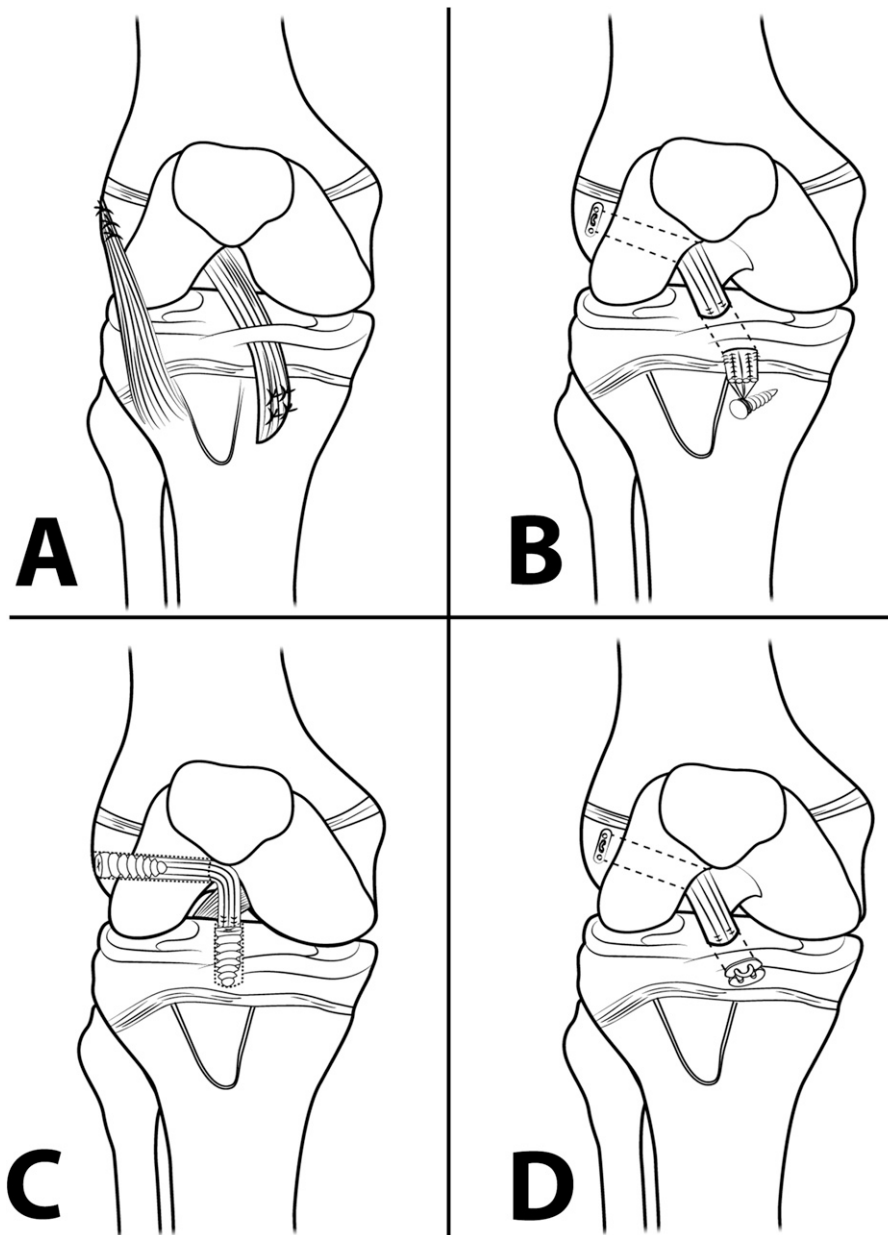


Fig. 4

Figs. 4-A through 4-D Surgical techniques. **Fig. 4-A** The Kocher technique is a combined intra-articular and extra-articular extraphyseal reconstruction in which the iliotibial band is rerouted via an over-the-top position posteriorly, passed under the intrameniscal ligament anteriorly on the tibia, and fixed with sutures. **Fig. 4-B** The Anderson technique is an intra-articular reconstruction that utilizes suspensory fixation on the femur and an extraphyseal screw and post on the tibia. **Fig. 4-C** The Ganley technique is an intra-articular all-epiphyseal reconstruction that uses interference screws for fixation on both the femur and the tibia. **Fig. 4-D** The Cordasco-Green technique is an intra-articular all-epiphyseal reconstruction that uses suspensory fixation on both the femur and the tibia.

been generally successful, with a mean IKDC score of 91.5, a mean Lysholm score of 93.5, and a return to the preinjury activity level in 88.8% of patients. The limb-length discrepancy is typically minimal, averaging 1.2 mm, but the operatively treated limb may range from 7 mm short to 7 mm long³⁵. Alternative graft choices, including the use of living-donor (parental) hamstring allograft, have been described and resulted in similar two-year functional outcomes con-

sisting of a mean IKDC score of 96, a mean Lysholm score of 97, and 100% return to strenuous activity without growth disturbance³⁶.

All-Epiphyseal Reconstruction

Several techniques involving all-epiphyseal ACL reconstruction have been reported. The Anderson technique (Fig. 4-B) is a two-incision, transephyseal reconstruction that is indicated

TABLE IV Review of the Literature on Surgical Outcomes Following Pediatric ACL Reconstruction: Study Demographics and Complications*

	First Author	No. of Patients	Mean Age (yr)	Mean Follow-up (mo)	Graft	Recurrent Instability	Reinjury
All-epiphyseal (physeal-sparing)	Anderson ⁴⁴ , 2003	12	13.3	49.2	Hamstring	NR	NR
	Guzzanti ⁴⁹ , 2003	8	11.2	69.2	Hamstring	NR	NR
	Hui ³⁶ , 2012	16	12	24.0	Hamstring auto./allo.	NR	NR
Extraphyseal (physeal-sparing)	Parker ⁵⁵ , 1994	6	13.3	33.2	Hamstring	NR	NR
	Nakhostine ⁵⁴ , 1995	5	14.0	52.8	Fascia lata	NR	None
	Kocher ³³ , 2005	44	10.3	63.6	ITB	NR	NR
Partial transphyseal	Bonnard ⁴⁷ , 2011	56	12.2	66.0	BTB	NR	5.4%
	Andrews ⁴⁵ , 1994	8	13.5	58.0	FL/Achilles allo.	None	NR
	Lo ⁵² , 1997	5	12.9	88.8	Hamstring/quad.	None	NR
Transphyseal	Lipscomb ⁵¹ , 1986	24	15.0	35.0	Hamstring	None	NR
	Aronowitz ⁴⁶ , 2000	15	14.0	25.0	Achilles allo.	NR	NR
	McIntosh ⁵³ , 2006	16	13.5	41.1	Hamstring	NR	12.5%
	Kocher ⁵⁶ , 2007	59	14.7	43.2	Hamstring	NR	NR
	Liddle ⁵⁰ , 2008	17	12.0	44.0	Hamstring	NR	5.9%
	Cohen ³⁵ , 2009	26	13.3	45.0	Hamstring	NR	6.7%
	Courvoisier ⁴⁸ , 2011	37	14.0	36.0 (median)	Hamstring	NR	8.1%

*LLD = limb-length discrepancy, NR = not reported, ITB = iliotibial band, BTB = bone-tendon-bone, and FL = fascia lata.

primarily in patients at Tanner stage I, II, or III (mean age, 13.3 years). The graft source is a four-strand hamstring autograft, which is secured by means of suspensory fixation on the femoral side and a screw and post on the tibial side. Studies have indicated a mean IKDC score of 96.5 with no clinically important growth disturbance when patients were followed to skeletal maturity (mean follow-up, 4.1 years)³⁷.

Ganley and colleagues developed an all-inside trans-epiphyseal reconstruction (Fig. 4-C) that is indicated in patients as early as Tanner stage I³⁸. This technique also uses an autologous four-strand hamstring autograft. An intraoperative computed tomography (CT) scan is made with use of an O-arm to ensure that guidewire placement is free of the physis prior to tunnel drilling. Graft fixation is performed with interference screws. Lawrence et al. reported knee stability (as indicated by Lachman and KT-1000 arthrometer testing) and return to preinjury activity levels with use of a custom ACL brace after this procedure in a series of three patients treated with this procedure³⁸. There was no evidence of growth disturbance in any of the patients during short-term follow-up.

The technique developed at our institution by two of the authors of this review (F.A.C. and D.W.G.) is also an all-inside transepihyseal reconstruction³⁹ (Fig. 4-D). This procedure is performed in patients who are Tanner stage I, II, or III and uses a quadrupled hamstring autograft, with intraoperative fluoroscopy to confirm guidewire placement prior to drilling of a socket (i.e., a blind hole, as opposed to an open-ended tunnel). Suspensory fixation is used on both the femur and the tibia. We prefer this method as it does not cross either physis, does not rely on interference fixation in softer epiphyseal bone, and facilitates anatomic restoration

of the ACL footprint, but clinical outcomes have not been published.

Technical Considerations and Treatment Algorithm

One unique consideration in skeletally immature patients is the effect of tunnel size on the physis. The prevalence of physeal arrest increases when physeal damage because of tunnel drilling involves >7% of the total physeal volume³⁴. Therefore, the graft radius may be the most important variable affecting the volume of physeal injury and potential arrest. Increasing the graft diameter from 6 to 11 mm will increase the volume percentage of physeal tissue removed from 2.3% to 7.8%. Additionally, increasing the tunnel drill angle from 45° to 70° will decrease the volume percentage removed from 4.1% to 3.1%, with a mean 0.2% decrease in physeal volume damaged for every 5° increase in tunnel angle^{34,40}. These factors have led to recommendations that tunnel diameters should be minimized (smaller-diameter graft) and that the tunnels should be placed in more central and relatively vertical positions. This conflicts with the principles and techniques currently utilized when performing ACL reconstruction in adults. Normal skeletal growth causes the volume percentage of the physis removed to decrease linearly with age. As expected, double-bundle techniques substantially increase the volumetric injury to the physis⁴⁰.

Likewise, tensioning of the soft-tissue graft may have an adverse effect on the growth plate, as excessive tensioning across an open physis may induce premature physeal closure. In a canine model, fascia lata autografts tensioned to 80 N across femoral and tibial tunnels led to substantial valgus deformity in the distal femur and significant varus deformity in the proximal tibia⁴¹.

We make radiographs postoperatively, acquire MRIs at six months, and make fifty-one-inch hip-to-ankle radiographs

TABLE IV (continued)

Reoperations	Return to Previous Level of Activity	Mean KT-1000 Difference	Mean Angular Deformity (deg)	Mean LLD	Complications
NR	NR	1.5 mm	None	None	NR
NR	NR	1.8 mm	None	None	NR
NR	100%	1.9 mm	None	None	NR
NR	80%	3.6 mm	None	None	NR
NR	100%	2.8 mm	NR	3 mm (15 mm in 1 patient)	NR
4.5%	NR	NR	None	None	NR
NR	62.5%	NR	NR	None	NR
NR	62.5% (unrelated to knee)	37.5% of pts. 3-5 mm	NR	None	NR
NR	80%	1.0 mm	None	0.8 mm	Recurrent non-ACL knee injury, 1
NR	87.5%	0.2 mm	NR	29.2%	NR
NR	84.2%	1.7 mm	None	None	NR
43.8%	87.5%	NR	None	Mean, 6.2 mm	NR
3%	NR	NR	None	None	Arthrofibrosis, 5.1%
NR	NR	None	None	None	Superficial infection, 5.9%
8.8%	88.8%	2 mm	0.46	Mean, 1.2 mm	NR
13.5%	NR	1 mm	NR	NR	NR

at one year to monitor for potential physeal disturbance. Patients are followed regularly until skeletal maturity. Although the precise rate of growth disturbance after ACL

reconstruction in children is not precisely known, a survey of 108 surgeons from the Herodicus Society and the ACL Study Group revealed fifteen cases of postoperative deformity.

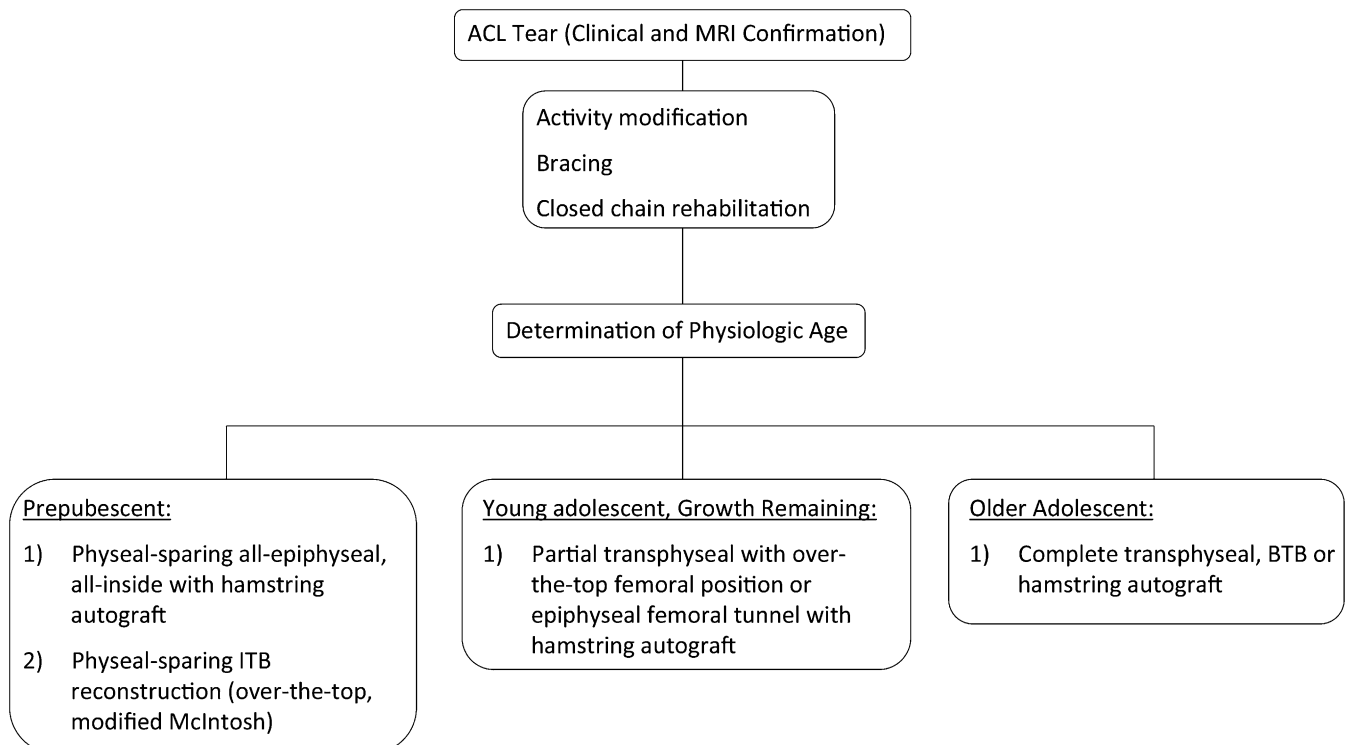


Fig. 5

Flowchart showing the treatment algorithm devised on the basis of the available data and technical considerations. Surgical decision-making is based on several patient-related variables: clinical instability, associated intra-articular pathology, patient activity level and goals, and skeletal age (remaining growth). Following an adequate trial of nonoperative management, ACL reconstruction is performed if the patient remains symptomatic, with persistent knee instability. MRI = magnetic resonance imaging, ITB = iliotibial band, and BTB = bone-tendon-bone.

These included distal femoral valgus deformity, tibial recurvatum, genu valgum, and substantial limb-length discrepancy. Risk factors included hardware placed across the lateral distal femoral physis, bone plugs placed across the distal femoral physis, a tunnel size of >12 mm, hardware extending across the apophysis of the tibial tubercle, lateral extra-articular tenodesis, or an over-the-top femoral position⁴². It is important to note, however, that there is minimal concern for growth arrest in children who may have open physes but are nearing skeletal maturity (approximately thirteen years old in girls and fifteen years old in boys).

Although protecting the physis of the skeletally immature patient is of great importance, mechanical considerations should also be noted. Recent data suggest that iliotibial band reconstruction best restores anteroposterior and rotational stability but may overconstrain the knee to rotational movements at some flexion angles⁴³. The clinical implications of this have not been investigated, but it is possible that overconstraint of the knee joint could be detrimental to the tibio-femoral articular cartilage.

The Authors' Surgical Treatment Algorithm

Our surgical treatment algorithm is outlined in Figure 5. After an ACL tear is confirmed clinically and with use of MRI in a skeletally immature patient, activity modification, bracing, and rehabilitation are initiated immediately. The patient's physiologic age is determined with use of the previously described methods. The decision to proceed with surgery is made on the basis of clinical instability, associated intra-articular pathology, the patient's activity level and goals, and skeletal age and growth remaining. In patients who are prepubescent, procedure options include a physeal-sparing all-epiphyseal all-inside reconstruction, a physeal-sparing Kocher reconstruction, or a partial or complete transphyseal reconstruction. In the young adolescent with growth remaining, a partial transphyseal reconstruction with an over-the-top femoral graft position or an epiphyseal femoral tunnel is performed. For adolescents who are near skeletal maturity, complete transphyseal bone-patellar tendon-bone autograft may be used.

Rehabilitation

Following an all-epiphyseal reconstruction, we utilize the rehabilitation protocol outlined in Table III. Phase I is initiated during the first four weeks postoperatively with the goals of full knee extension, 90° of passive flexion, patellar mobility, improved quadriceps contraction, and a home exercise program. Phase II spans the period from four to eight weeks postoperatively and emphasizes range of motion from full extension to 125°, a normalized gait while weight-bearing as tolerated, and neuromuscular control to perform a single-leg stance without pain. Phase III spans the period from eight through sixteen weeks postoperatively and has the goals of full range of knee motion, improved quadriceps and core strength, and eccentric quadriceps control. Phase IV spans the period from sixteen to twenty weeks postoperatively and focuses on

maximization of strength and flexibility and demonstration of an athletic ready-position stance. Additionally, the patient is assessed by a trained physical therapist at sixteen weeks postoperatively for proper biomechanics, with the goal of prevention of further ACL injury. Phase V extends to twenty-eight weeks and emphasizes symptom-free running, flexibility, and dynamic control with jumping and landing. An independent gym program is also prescribed on the basis of the patient's individualized sporting activities and rate of progress with supervised physical therapy. The final postoperative phase begins at twenty-eight weeks and continues until full return to athletic activity. By the end of this supervised rehabilitation protocol, the patient should be able to perform a hop test with >85% limb symmetry, lack apprehension with sport-specific movements, display dynamic control with sport-specific movements, have flexibility commensurate with sport participation, and demonstrate compliance with functional bracing.

Surgical Outcomes

A review of the literature on surgical outcomes following pediatric ACL reconstruction is outlined in Tables IV and V. Clinical outcomes following ACL reconstruction in children and adolescents are much better than those noted following nonsurgical management^{33,35,36,44-55}. The outcome of physeal-sparing reconstructions^{33,36,44,47,49,54,55} has been documented at a mean follow-up of two to six years and was successful. Patients reached skeletal maturity without evidence of limb-length discrepancy or angular deformity. Mean IKDC and Lysholm scores ranged from 94 to 97 in several studies^{33,36,44,47,49,54,55}.

Favorable results have also been demonstrated for partial transphyseal^{45,52} and complete transphyseal reconstructions^{35,36,46,48,50,51,53,55}, with no or minimal limb-length discrepancy. When limb-length discrepancy did occur, as was the case in up to 30% of patients⁵¹, it was clinically unimportant (mean, 1.2 to 6.2 mm as measured with use of a combination of full-length hip-to-ankle radiographs and scanograms³⁵ or a combination of the distance from the anterior superior iliac spine to the medial malleolus and confirmation with standing hip-to-ankle radiographs⁵³). To our knowledge, no information on angular deformities has been published. At a mean follow-up of two to four years, mean IKDC scores ranging from 90 to 92 and Lysholm scores ranging from 91 to 99 have been reported^{35,46,50,53,56}. Arthrofibrosis⁵⁶ and superficial infections⁵⁵ are uncommon complications, but when reported have occurred in 5% of patients. There is typically a low rate of revision surgery (3% to 13%; Table IV), which is often due to reinjury, although a 44% reoperation rate for graft disruption, removal of prominent hardware, and failed meniscal repair was noted in one study of sixteen patients⁵³.

Outcomes of ACL reconstruction in pediatric and adolescent patients have been generally favorable. Heterogeneity of patient developmental status, surgical technique, graft choice, fixation, and outcome measures preclude quality meta-analysis. However, large retrospective case series have revealed higher

TABLE V Review of the Literature on Surgical Outcomes Following Pediatric ACL Reconstruction: Clinical Outcome Measures*

	First Author	Mean IKDC Score	IKDC Class	Mean Lysholm Score	Mean Tegner Score	Mean Noyes Score	Mean OAK Score	Mean HSS Score
All-epiphyseal (physeal-sparing)	Anderson ⁴⁴ , 2003	96.5	100% A or B	NR	NR	NR	NR	NR
	Guzzanti ⁴⁹ , 2003	NR	NR	NR	NR	NR	97	NR
	Hui ³⁶ , 2012	96	94% A or B	97	NR	NR	NR	NR
Extraphyseal (physeal-sparing)	Parker ⁵⁵ , 1994	NR	NR	95.2	NR	97.6	NR	96.6/100
	Nakhostine ⁵⁴ , 1995	NR	NR	NR	NR	NR	NR	NR
	Kocher ³³ , 2005	96.7	NR	95.7	NR	NR	NR	NR
Partial transphyseal	Bonnard ⁴⁷ , 2011	94.4	80% A or B	NR	6.75	NR	NR	NR
	Andrews ⁴⁵ , 1994	NR	NR	NR	NR	NR	NR	NR
	Lo ⁵² , 1997	NR	80% A	NR	NR	NR	NR	NR
Transphyseal	Lipscomb ⁵¹ , 1986	NR	NR	NR	NR	NR	NR	45.9/50
	Aronowitz ⁴⁶ , 2000	NR	NR	97	NR	NR	NR	NR
	McIntosh ⁵³ , 2006	89.9	NR	98.8	NR	NR	NR	NR
	Kocher ⁵⁶ , 2007	89.5	NR	91.1	NR	NR	NR	NR
	Liddle ⁵⁰ , 2008	NR	NR	97.5	7.9	NR	NR	NR
	Cohen ³⁵ , 2009	91.5	NR	93.5	NR	NR	NR	NR
	Courvoisier ⁴⁸ , 2011	NR	87% A or B	NR	NR	NR	NR	NR

*IKDC = International Knee Documentation Committee, OAK = Orthopädische Arbeitsgruppe Knie, HSS = Hospital for Special Surgery, and NR = not reported.


failure rates in patients less than eighteen years old compared with adults^{57,58} and lower rates of return to athletic activity after revision surgery⁵⁹.

Overview

Intrasubstance tears of the ACL have been observed with increasing frequency in pediatric patients as a result of a recent rise in athletic activity. We have highlighted pediatric ACL anatomy and the anatomic considerations unique to ACL reconstruction in children. Nonoperative management results in continued instability resulting in high rates of meniscal and chondral damage and inability to return to athletic activity. Several transphyseal and physeal-sparing surgical reconstruction techniques have been described and appear to yield superior results compared with nonoperative management, without substantial growth disturbance. With proper rehabilitation, children are returning to their preoperative level of athletic activity and have excellent objective outcome scores. Nevertheless, the failure rate following ACL reconstruction is higher in young athletes compared with athletes over the age of eighteen years. This information should be conveyed to the patient and the family preoperatively. A detailed understanding of the pediatric ACL and the unique aspects of pediatric knee anatomy is crucial to performing effective and safe ACL reconstruction in pediatric patients. Children should be monitored postoperatively

by means of regular clinical and radiographic examination through skeletal maturity to verify that no substantial growth disturbance is occurring.

Appendix

 A video demonstrating pediatric ACL reconstruction is available with the online version of this article as a data supplement at jbjs.org. ■

Note: The authors thank Cyndi Conklin for her assistance in producing the images in Figure 4.

Peter D. Fabricant, MD
Kristofer J. Jones, MD
Demetris Delos, MD
Frank A. Cordasco, MD, MS
Robert G. Marx, MD, MSc
Andrew D. Pearle, MD
Russell F. Warren, MD
Daniel W. Green, MD, MS
Sports Medicine and Shoulder Service (F.A.C., R.G.M., A.D.P., R.F.W.)
and Section of Pediatric Orthopaedic Surgery (D.W.G.),
Department of Orthopaedic Surgery (P.D.F., K.J.J., D.D.),
Hospital for Special Surgery,
535 East 70th Street,
New York, NY 10021.
E-mail address for P.D. Fabricant: fabricantp@hss.edu

References

1. Behr CT, Potter HG, Paletta GA Jr. The relationship of the femoral origin of the anterior cruciate ligament and the distal femoral physeal plate in the skeletally immature knee. An anatomic study. *Am J Sports Med.* 2001 Nov-Dec;29(6):781-7.

2. Kopf S, Pombo MW, Szczodry M, Irrgang JJ, Fu FH. Size variability of the human anterior cruciate ligament insertion sites. *Am J Sports Med.* 2011 Jan;39(1):108-13.

3. Kepler C, Potter H, Green DW, Hammoud S. Intercondylar notch dimensions and growth patterns in young pediatric patients. Presented at the Annual Meeting of the American Academy of Orthopaedic Surgeons; 2011 Feb 16-19; San Diego, CA.
4. Liu RW, Farrow LD, Messerschmitt PJ, Gilmore A, Goodfellow DB, Cooperman DR. An anatomical study of the pediatric intercondylar notch. *J Pediatr Orthop*. 2008 Mar;28(2):177-83.
5. Gilchrist J, Mandelbaum BR, Melancon H, Ryan GW, Silvers HJ, Griffin LY, Watanabe DS, Dick RW, Dvorak J. A randomized controlled trial to prevent noncontact anterior cruciate ligament injury in female collegiate soccer players. *Am J Sports Med*. 2008 Aug;36(8):1476-83.
6. Hattori K, Sano H, Komatsuda T, Saijo Y, Sugita T, Itoi E. Effect of estrogen on tissue elasticity of the ligament proper in rabbit anterior cruciate ligament: measurements using scanning acoustic microscopy. *J Orthop Sci*. 2010 Jul;15(4):584-8.
7. Komatsuda T, Sugita T, Sano H, Kusakabe T, Watanuki M, Yoshizumi Y, Murakami T, Hashimoto M, Kokubun S. Does estrogen alter the mechanical properties of the anterior cruciate ligament? An experimental study in rabbits. *Acta Orthop*. 2006 Dec;77(6):973-80.
8. Drago J, Padrez K, Workman R, Lindsey DP. The effect of relaxin on the female anterior cruciate ligament: Analysis of mechanical properties in an animal model. *Knee*. 2009 Jan;16(1):69-72.
9. Park SK, Stefanyshyn DJ, Loitz-Ramage B, Hart DA, Ronsky JL. Changing hormone levels during the menstrual cycle affect knee laxity and stiffness in healthy female subjects. *Am J Sports Med*. 2009 Mar;37(3):588-98.
10. Zazulak BT, Paterno M, Myer GD, Romani WA, Hewett TE. The effects of the menstrual cycle on anterior knee laxity: a systematic review. *Sports Med*. 2006;36(10):847-62.
11. Alentorn-Geli E, Myer GD, Silvers HJ, Samitier G, Romero D, Lázaro-Haro C, Cugat R. Prevention of non-contact anterior cruciate ligament injuries in soccer players. Part 1: mechanisms of injury and underlying risk factors. *Knee Surg Sports Traumatol Arthrosc*. 2009 Jul;17(7):705-29.
12. Harmon KG, Ireland ML. Gender differences in noncontact anterior cruciate ligament injuries. *Clin Sports Med*. 2000 Apr;19(2):287-302.
13. Drakos MC, Hillstrom H, Voos JE, Miller AN, Kraszewski AP, Wickiewicz TL, Warren RF, Allen AA, O'Brien SJ. The effect of the shoe-surface interface in the development of anterior cruciate ligament strain. *J Biomech Eng*. 2010 Jan;132(1):011003.
14. Brophy RH, Gamradt SC, Ellis SJ, Barnes RP, Rodeo SA, Warren RF, Hillstrom H. Effect of turf toe on foot contact pressures in professional American football players. *Foot Ankle Int*. 2009 May;30(5):405-9.
15. Krych AJ, Pitts RT, Dajani KA, Stuart MJ, Levy BA, Dahm DL. Surgical repair of meniscal tears with concomitant anterior cruciate ligament reconstruction in patients 18 years and younger. *Am J Sports Med*. 2010 May;38(5):976-82.
16. Sankar WN, Wells L, Sennett BJ, Wiesel BB, Ganley TJ. Combined anterior cruciate ligament and medial collateral ligament injuries in adolescents. *J Pediatr Orthop*. 2006 Nov-Dec;26(6):733-6.
17. Piasecki DP, Spindler KP, Warren TA, Andrich JT, Parker RD. Intraarticular injuries associated with anterior cruciate ligament tear: findings at ligament reconstruction in high school and recreational athletes. An analysis of sex-based differences. *Am J Sports Med*. 2003 Jul-Aug;31(4):601-5.
18. Knutsen G, Drogset JO, Engebretsen L, Grøntvedt T, Isaksen V, Ludvigsen TC, Roberts S, Solheim E, Strand T, Johansen O. A randomized trial comparing autologous chondrocyte implantation with microfracture. Findings at five years. *J Bone Joint Surg Am*. 2007 Oct;89(10):2105-12.
19. Stanitski CL, Harvell JC, Fu F. Observations on acute knee hemarthrosis in children and adolescents. *J Pediatr Orthop*. 1993 Jul-Aug;13(4):506-10.
20. Lee K, Siegel MJ, Lau DM, Hildebolt CF, Matava MJ. Anterior cruciate ligament tears: MR imaging-based diagnosis in a pediatric population. *Radiology*. 1999 Dec;213(3):697-704.
21. Zerlin JM, Hernandez RJ. Approach to skeletal maturation. *Hand Clin*. 1991 Feb;7(1):53-62.
22. Acheson RM, Fowler G, Fry EI, Janes M, Koski K, Urbano P, Werfftenboschij VA. Studies in the reliability of assessing skeletal maturity from x-rays. I. Greulich-Pyle Atlas. *Hum Biol*. 1963 Sep;35:317-49.
23. Heyworth BE, Osei D, Fabricant PD, Green DW, Doyle SM, Widmann RF, Scher DM, Schneider R, Cahill PJ, Herman MJ. A new, validated shorthand method for determining bone age. Presented at the Annual Meeting of the American Academy of Orthopaedic Surgeons; 2011 Feb 16-19; San Diego, CA.
24. Amoczky SP, Rubin RM, Marshall JL. Microvasculature of the cruciate ligaments and its response to injury. An experimental study in dogs. *J Bone Joint Surg Am*. 1979 Dec;61(8):1221-9.
25. Kocher MS, Micheli LJ, Zurakowski D, Luke A. Partial tears of the anterior cruciate ligament in children and adolescents. *Am J Sports Med*. 2002 Sep-Oct;30(5):697-703.
26. McCarroll JR, Rettig AC, Shelbourne KD. Anterior cruciate ligament injuries in the young athlete with open physes. *Am J Sports Med*. 1988 Jan-Feb;16(1):44-7.
27. Graf BK, Lange RH, Fujisaki CK, Landry GL, Saluja RK. Anterior cruciate ligament tears in skeletally immature patients: meniscal pathology at presentation and after attempted conservative treatment. *Arthroscopy*. 1992;8(2):229-33.
28. Aichroth PM, Patel DV, Zorrilla P. The natural history and treatment of rupture of the anterior cruciate ligament in children and adolescents. A prospective review. *J Bone Joint Surg Br*. 2002 Jan;84(1):38-41.
29. Mizuta H, Kubota K, Shiraiishi M, Otsuka Y, Nagamoto N, Takagi K. The conservative treatment of complete tears of the anterior cruciate ligament in skeletally immature patients. *J Bone Joint Surg Br*. 1995 Nov;77(6):890-4.
30. Henry J, Chotel F, Chouteau J, Fessy MH, Béard J, Moyon B. Rupture of the anterior cruciate ligament in children: early reconstruction with open physes or delayed reconstruction to skeletal maturity? *Knee Surg Sports Traumatol Arthrosc*. 2009 Jul;17(7):748-55.
31. Millett PJ, Willis AA, Warren RF. Associated injuries in pediatric and adolescent anterior cruciate ligament tears: does a delay in treatment increase the risk of meniscal tear? *Arthroscopy*. 2002 Nov-Dec;18(9):955-9.
32. Lawrence JT, Argawal N, Ganley TJ. Degeneration of the knee joint in skeletally immature patients with a diagnosis of an anterior cruciate ligament tear: is there harm in delay of treatment? *Am J Sports Med*. 2011 Dec;39(12):2582-7.
33. Kocher MS, Garg S, Micheli LJ. Physal sparing reconstruction of the anterior cruciate ligament in skeletally immature prepubescent children and adolescents. *J Bone Joint Surg Am*. 2005 Nov;87(11):2371-9.
34. Guzzanti V, Falciglia F, Gigante A, Fabbriani C. The effect of intra-articular ACL reconstruction on the growth plates of rabbits. *J Bone Joint Surg Br*. 1994 Nov;76(6):960-3.
35. Cohen M, Ferretti M, Quarteiro M, Marcondes FB, de Hollanda JP, Amaro JT, Abdalla RJ. Transphyseal anterior cruciate ligament reconstruction in patients with open physes. *Arthroscopy*. 2009 Aug;25(8):831-8.
36. Hui C, Roe J, Ferguson D, Waller A, Salmon L, Pinczewski L. Outcome of anatomic transphyseal anterior cruciate ligament reconstruction in Tanner stage 1 and 2 patients with open physes. *Am J Sports Med*. 2012 May;40(5):1093-8.
37. Anderson AF. Transepiphyseal replacement of the anterior cruciate ligament using quadruple hamstring grafts in skeletally immature patients. *J Bone Joint Surg Am*. 2004;86(Pt 2)(Suppl 1):201-9.
38. Lawrence JT, Bowers AL, Belding J, Cody SR, Ganley TJ. All-epiphyseal anterior cruciate ligament reconstruction in skeletally immature patients. *Clin Orthop Relat Res*. 2010 Jul;468(7):1971-7.
39. McCarthy MM, Graziano J, Green DW, Cordasco FA. All-epiphyseal, all-inside anterior cruciate ligament reconstruction technique for skeletally immature patients. *Arthrosc Techniques*. In press.
40. Shea KG, Grimm NL, Belzer JS. Volumetric injury of the distal femoral physis during double-bundle ACL reconstruction in children: a three-dimensional study with use of magnetic resonance imaging. *J Bone Joint Surg Am*. 2011 Jun 1;93(11):1033-8.
41. Edwards TB, Greene CC, Baratta RV, Zieske A, Willis RB. The effect of placing a tensioned graft across open growth plates. A gross and histologic analysis. *J Bone Joint Surg Am*. 2001 May;83(5):725-34.
42. Kocher MS, Saxon HS, Hovis WD, Hawkins RJ. Management and complications of anterior cruciate ligament injuries in skeletally immature patients: survey of the Herodicus Society and The ACL Study Group. *J Pediatr Orthop*. 2002 Jul-Aug;22(4):452-7.
43. Kennedy A, Coughlin DG, Metzger MF, Tang R, Pearle AD, Lotz JC, Feeley BT. Biomechanical evaluation of pediatric anterior cruciate ligament reconstruction techniques. *Am J Sports Med*. 2011 May;39(5):964-71.
44. Anderson AF. Transepiphyseal replacement of the anterior cruciate ligament in skeletally immature patients. A preliminary report. *J Bone Joint Surg Am*. 2003 Jul;85(7):1255-63.
45. Andrews M, Noyes FR, Barber-Westin SD. Anterior cruciate ligament allograft reconstruction in the skeletally immature athlete. *Am J Sports Med*. 1994 Jan-Feb;22(1):48-54.
46. Aronowitz ER, Ganley TJ, Goode JR, Gregg JR, Meyer JS. Anterior cruciate ligament reconstruction in adolescents with open physes. *Am J Sports Med*. 2000 Mar-Apr;28(2):168-75.
47. Bonnard C, Fournier J, Babusiaux D, Planchenault M, Bergerault F, de Courtivron B. Physal-sparing reconstruction of anterior cruciate ligament tears in children: results of 57 cases using patellar tendon. *J Bone Joint Surg Br*. 2011 Apr;93(4):542-7.
48. Courvoisier A, Grimaldi M, Plaweski S. Good surgical outcome of transphyseal ACL reconstruction in skeletally immature patients using four-strand hamstring graft. *Knee Surg Sports Traumatol Arthrosc*. 2011 Apr;19(4):588-91.
49. Guzzanti V, Falciglia F, Stanitski CL. Physal-sparing intraarticular anterior cruciate ligament reconstruction in preadolescents. *Am J Sports Med*. 2003 Nov-Dec;31(6):949-53.
50. Liddle AD, Imbuldeniya AM, Hunt DM. Transphyseal reconstruction of the anterior cruciate ligament in prepubescent children. *J Bone Joint Surg Br*. 2008 Oct;90(10):1317-22.

- 51.** Lipscomb AB, Anderson AF. Tears of the anterior cruciate ligament in adolescents. *J Bone Joint Surg Am.* 1986 Jan;68(1):19-28.
- 52.** Lo IK, Kirkley A, Fowler PJ, Miniaci A. The outcome of operatively treated anterior cruciate ligament disruptions in the skeletally immature child. *Arthroscopy.* 1997 Oct;13(5):627-34.
- 53.** McIntosh AL, Dahm DL, Stuart MJ. Anterior cruciate ligament reconstruction in the skeletally immature patient. *Arthroscopy.* 2006 Dec;22(12):1325-30.
- 54.** Nakhostine M, Bollen SR, Cross MJ. Reconstruction of mid-substance anterior cruciate rupture in adolescents with open physes. *J Pediatr Orthop.* 1995 May-Jun;15(3):286-7.
- 55.** Parker AW, Drez D Jr, Cooper JL. Anterior cruciate ligament injuries in patients with open physes. *Am J Sports Med.* 1994 Jan-Feb;22(1):44-7.
- 56.** Kocher MS, Smith JT, Zoric BJ, Lee B, Micheli LJ. Transphyseal anterior cruciate ligament reconstruction in skeletally immature pubescent adolescents. *J Bone Joint Surg Am.* 2007 Dec;89(12):2632-9.
- 57.** Kaeding CC, Aros B, Pedroza A, Pifel E, Amendola A, Andrish JT, et al. Allograft versus autograft anterior cruciate ligament reconstruction. Predictors of failure from a MOON prospective longitudinal cohort. *Sports Health* 2011;3(1):73,73-81.
- 58.** Shelbourne KD, Gray T, Haro M. Incidence of subsequent injury to either knee within 5 years after anterior cruciate ligament reconstruction with patellar tendon autograft. *Am J Sports Med.* 2009 Feb;37(2):246-51.
- 59.** Reinhardt KR, Hammoud S, Bowers AL, Umunna BP, Cordasco FA. Revision ACL reconstruction in skeletally mature athletes younger than 18 years. *Clin Orthop Relat Res.* 2012 Mar;470(3):835-42.