

# In-Office Needle Arthroscopy: A Systematic Review of Indications and Clinical Utility



Kailai Zhang, B.H.Sc., Raphael J. Crum, B.Sc., Kristian Samuelsson, M.D., Ph.D., M.Sc.,  
Edwin Cadet, M.D., Olufemi Rolland Ayeni, M.D., Ph.D., M.Sc., and  
Darren de SA, M.D., F.R.C.S.C.

**Purpose:** This review explores the current literature regarding both the clinical indications and utility of minimally invasive in-office needle arthroscopy (IONA) relative to conventional imaging modalities. **Methods:** In compliance with R-AMSTAR (Revised Assessment of Multiple Systematic Reviews) and PRISMA (Preferred Reporting Items for Systematic Reviews and Meta-analyses) guidelines, 3 databases (MEDLINE, Embase, and PubMed) were searched in July 2018, in addition to the conference abstract databases of 5 prominent meetings between 2013 and 2018, for studies using IONA for diagnostic purposes. Study quality was assessed with the Methodological Index for Non-Randomized Studies (MINORS) criteria. **Results:** Among 932 conference abstracts and 369 studies identified, 11 publications involving 404 patients (395 knees and 9 shoulders) were included, with 9 clinical studies and 2 cost analyses. The median Methodological Index for Non-Randomized Studies (MINORS) score was 9 for noncomparative and 23 for comparative studies. Among the 9 clinical studies, IONA had a superior sensitivity, specificity, positive predictive value, and negative predictive value to magnetic resonance imaging (MRI) in the evaluation of knee osteoarthritis, anterior cruciate ligament insufficiency, and meniscal tears. IONA was comparable or inferior to MRI in the same parameters for the diagnosis of osteochondral defects and rotator cuff tears. In the 2 cost analyses, IONA had lower costs when used in place of MRI for treatment algorithms involving medial meniscal tears and rotator cuff tears but not lateral meniscal tears. **Conclusions:** IONA holds potential for cost savings and improved diagnostic accuracy relative to MRI, primarily for intra-articular meniscal, ligamentous, and chondral defects of the knee. However, its current indications for use in other joints are limited to rotator cuff tears in the shoulder, making its diagnostic value in other joints much more limited. The current quality and breadth of evidence are significantly lacking, with numerous practical shortcomings. To improve acceptance of IONA, priority should be placed on establishing defined protocols, indications, contraindications, and patient perspectives for the procedure. **Level of Evidence:** Level IV, systematic review of Level II, III, and IV studies.

See commentary on page 2722

In addition to a history and physical examination, the confirmation of intra-articular pathology relies on a combination of modalities, including plain radiographs,

From Michael G. DeGroot School of Medicine (K.Z.) and Division of Orthopaedic Surgery, McMaster University (O.R.A., D.d.S.), Hamilton, Ontario, Canada; Pittsburgh School of Medicine, University of Pittsburgh (R.J.C.), Pittsburgh, Pennsylvania, U.S.A.; Sahlgrenska Academy, University of Gothenburg (K.S.), Goteborg, Sweden; and Raleigh Orthopaedic Clinic (E.C.), Raleigh, North Carolina, U.S.A.

The authors report no conflicts of interest in the authorship and publication of this article. Full ICMJE author disclosure forms are available for this article online, as supplementary material.

Received December 14, 2018; accepted March 16, 2019.

Address correspondence to Darren de Sa, M.D., Division of Orthopaedic Surgery, McMaster University, 1280 Main Street West, Hamilton, Ontario L8S4L8, Canada. E-mail: [darren.desa@medportal.ca](mailto:darren.desa@medportal.ca)

© 2019 by the Arthroscopy Association of North America

0749-8063/181516/\$36.00

<https://doi.org/10.1016/j.arthro.2019.03.045>

magnetic resonance imaging (MRI), and standard arthroscopy, to name a few.<sup>1-3</sup> In particular, MRI remains the gold standard for preoperative diagnosis and characterization of soft-tissue derangements, providing vital information regarding the necessity of operative intervention and preoperative planning.<sup>4</sup> Despite its widespread use in this context, MRI does possess several well-documented contraindications and limitations. Moreover, this modality often requires that accurate identification of intra-articular abnormalities be facilitated by a trained musculoskeletal radiologist.<sup>4-6</sup> As a result, multiple office visits are often necessary for each patient when considering his or her initial consultation, completion of MRI, review of the results with the surgeon, and eventual definitive management. These logistic shortcomings, in the face of increasing wait times and limited availability of MRI worldwide,

further strain available resources and delay intervention. For example, in Ontario, Canada, the average time between initial referral to an orthopaedic surgeon and the date of operation ranges from 155 to 216 days for knee arthroscopy and from 187 to 248 days for shoulder surgery (including arthroscopy)—influenced in large part by the 35- to 96-day delay between consultation and performance of MRI.<sup>7,8</sup> This duration is naturally coupled with a presumed decreased level of productivity and quality of life, in addition to potential progression of the causative pathology itself.

In-office needle arthroscopy (IONA) represents an emerging diagnostic modality with promise to help address these delays in patient care. In brief, the procedure involves the insertion of a 14-gauge, high-definition arthroscope into a joint to directly visualize the intra-articular space.<sup>9-11</sup> Originally pioneered in the 1990s with similar equipment and anesthetic requirements to arthroscopy, advances in technology have made IONA a viable procedure in the office setting with the patient under local anesthetic alone.<sup>11</sup> Although the surgical instrumentation and anesthetic conditions afforded by the operating theater facilitate a more thorough evaluation of articular structures, IONA can provide the consultant with an on-demand view, in the office setting, highly akin to intraoperative views.<sup>3,12</sup> Thus, IONA can be used alone to diagnose intra-articular pathology and/or in conjunction with MRI to consolidate equivocal findings. Beyond the diagnostic value of the procedure, IONA may be advantageous to both the patient and surgeon relative to imaging techniques. The similarity of views between IONA and arthroscopy allows for enhanced preoperative planning, potentially shortening procedure times.<sup>12,13</sup> Several cost analyses have projected savings of up to U.S. \$400 per person relative to MRI with use of IONA in this context.<sup>3,13</sup> However, despite these apparent benefits, IONA is not currently widely used because of the limited comparisons to existing diagnostic modalities in the literature, the lack of availability of the technology, the learning curve of the procedure, a lack of guidelines for use, and inconsistency with insurance reimbursement.<sup>3,9-11,13</sup>

The purpose of this systematic review was to evaluate the current literature regarding clinical indications for using IONA, with a specific focus on elucidating its accuracy and costs relative to other diagnostic modalities. We hypothesized that IONA—by nature of being able to directly visualize intra-articular structures—would outperform, from a diagnostic and cost-effective standpoint, current MRI modalities.

## Methods

### Search Strategy

Three online databases (Embase, MEDLINE, and PubMed) were searched from database inception to July 15, 2018, using an a priori search strategy. The following

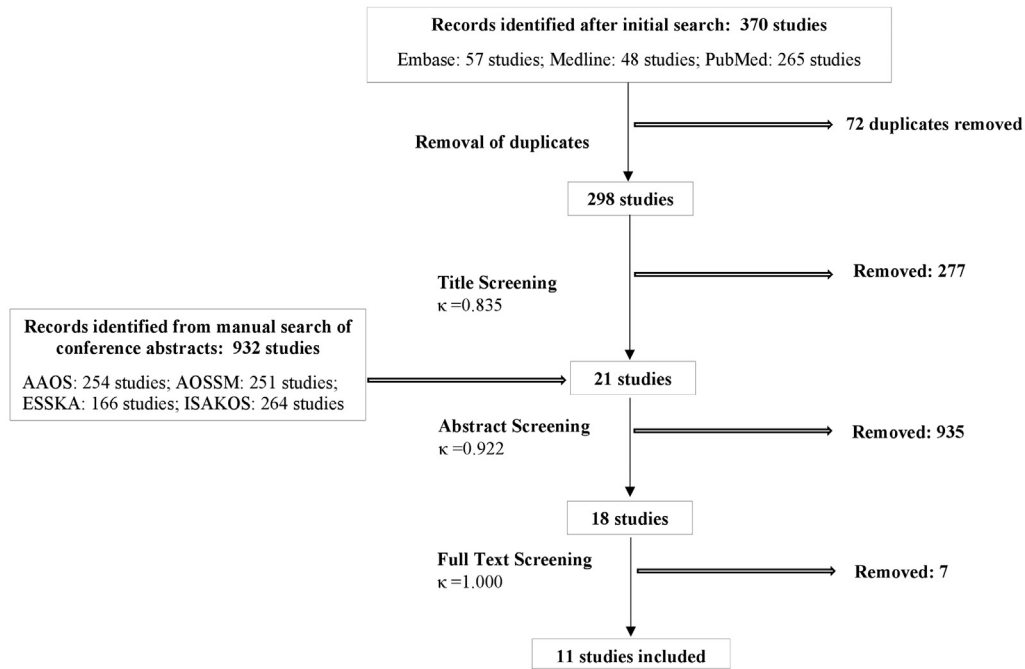
Medical Subject Headings (MeSH) terms were used in the search: “‘Arthrosc\*’ AND ‘Diagnostic’ AND (‘In-office’ OR ‘Needle’).” In addition, the conference abstracts between 2013 and 2018 from the American Academy of Orthopaedic Surgeons (AAOS); American Orthopaedic Society for Sports Medicine (AOSSM); European Society of Sports Traumatology, Knee Surgery & Arthroscopy (ESSKA); and International Society of Arthroscopy, Knee Surgery & Orthopaedic Sports Medicine (ISAKOS) were individually searched for potential additional studies. The PRISMA (Preferred Reporting Items for Systematic Reviews and Meta-analyses) and R-AMSTAR (Revised Assessment of Multiple Systematic Reviews) guidelines were adhered to in the development of this study, and [Figure 1](#) illustrates the search strategy used.<sup>14,15</sup> The specific inclusion criteria were (1) all levels of evidence, (2) human studies, (3) studies written in English, (4) studies using IONA for diagnostic purposes, and (5) studies reporting diagnostic outcomes and/or costs of treatment. The specific exclusion criteria were (1) cadaveric studies, (2) review articles or book chapters, (3) studies using IONA for therapeutic purposes, and (4) rheumatologic studies.

### Study Screening

Two reviewers (K.Z., R.C.) independently screened titles, abstracts, and full texts of retrieved studies. Discrepancies at the title and abstract screening stages were included through subsequent stages to ensure a thorough review, with discrepancies at the full-text stage resolved by consensus between reviewers. If consensus could not be reached, a senior reviewer (D.d.S.) was consulted for resolution. The reference sections of included studies were additionally screened to identify any studies that were not identified in the initial search. Inter-reviewer agreement for each stage of study screening was calculated with the  $\kappa$  statistic, with values categorized a priori as follows:  $\kappa$  of 0.81 to 0.99 was considered almost perfect agreement;  $\kappa$  of 0.61 to 0.80, substantial agreement;  $\kappa$  of 0.41 to 0.60, moderate agreement;  $\kappa$  of 0.21 to 0.40, fair agreement; and  $\kappa$  of 0.20 or less, slight agreement.

### Quality Assessment

Quality assessment of included nonrandomized studies was completed using the Methodological Index for Non-Randomized Studies (MINORS) criteria, with maximum scores of 16 for noncomparative and 24 for comparative studies.<sup>16</sup> The levels of evidence of included studies were assessed with the American Academy of Orthopaedic Surgeons (AAOS) classification system for the orthopaedic literature.<sup>17</sup> The average MINORS score across studies was calculated and reported separately for noncomparative and comparative studies. We considered a score of less than 10 to indicate poor quality for noncomparative studies; 10 to 13, moderate quality; and greater than 13, good quality. For comparative studies, a score of less than 15



**Fig 1.** PRISMA. (Preferred Reporting Items for Systematic Reviews and Meta-analyses) flowchart showing screening of initial title search and exclusions. The search was conducted on July 15, 2018. Screening was completed in duplicate by 2 independent reviewers, with disagreements at the title and abstract screening stages advanced to the subsequent stage. Disagreements at the full-text screening stage were brought to the senior author and resolved based on the senior author's judgment. AAOS, American Academy of Orthopaedic Surgeons; AOSSM, American Orthopaedic Society for Sports Medicine; ESSKA, European Society of Sports Traumatology, Knee Surgery & Arthroscopy; ISAKOS, International Society of Arthroscopy, Knee Surgery & Orthopaedic Sports Medicine.

was considered poor quality; 15 to 19, moderate quality; and greater than 19, good quality.

### Data Abstraction

Relevant data from included articles were abstracted into a Microsoft Excel (Microsoft, Redmond, WA) spreadsheet. The standardized form included (1) study design and characteristics (year, level of evidence, country), (2) demographic data (joints involved, age, sex, diagnostic modalities used, pathologies investigated), (3) diagnostic accuracy of included modalities, (4) relative costs of diagnostic modalities, and (5) post-procedure complications with associated costs. All figures included were reported in U.S. dollars.

### Statistical Analysis

Descriptive statistics, including frequencies, standard deviations, and ranges, were calculated and presented as appropriate for recorded data. Weighted means were calculated across studies and stratified by treatment approach. All statistics were calculated and figures were created with use of GraphPad software (version 6; GraphPad Software, La Jolla, CA). Because of heterogeneous and limited reporting, data could not be combined in a meta-analysis, and all data were summarized descriptively according to the recommendations of Dhawan et al.<sup>18</sup>

## Results

### Demographic Characteristics

Among 932 conference abstracts and 369 studies identified in the initial search, a total of 11 articles involving 404 patients, with 395 knees and 9 shoulders, were eligible for this study. Of these, 9 were clinical studies and 2 were cost analyses. Ten studies included knees alone, whereas 1 study included both knees and shoulders. The  $\kappa$  value was nearly perfect at all stages of study screening and is detailed in Figure 1. Across clinical studies, 5 used the VisionScope Imaging System (VisionScope Technologies, Littleton, CO), 3 used the mi-eye 2 system (Trice Medical, Malvern, PA), and 3 used an unspecified model of needle arthroscope. The level of evidence across included studies ranged from Level II to IV, with 6 Level IV, 2 Level III, and 3 Level II studies. The median MINORS score was 9 for noncomparative and 23 for comparative studies, with 4 moderate-quality and 7 poor-quality studies per our aforementioned definitions. In both noncomparative and comparative studies, deficits in MINORS scoring were primarily a lack of unbiased endpoint evaluation, lack of prospective calculation of the sample size, and lack of prospective data collection. Of note, no specification was made for morphology or type of either rotator cuff tear or meniscal tear across included studies (Table 1).

**Table 1.** Study Demographic Characteristics, Needle Arthroscope Model, and Pathologies Investigated

| Authors                                | Title  | Level of Evidence   | MINORS Score  | No. of Shoulders | No. of Knees | Needle Arthroscope Model   | Pathologies Investigated   |
|--|--|---------------------|---------------|------------------|--------------|----------------------------|--|
| Gill and Carroll <sup>19</sup> (2013)  | Cost-effective in-office diagnostic imaging: Visionscope versus MRI  | IV                  | NA (abstract) | 9                | 36           | VisionScope Imaging System | NR   |
| Xerogeanes et al. <sup>20</sup> (2014) | A prospective multi-center clinical trial to compare efficiency, accuracy and safety of the Visionscope imaging system compared to MRI and diagnostic arthroscopy  | II                  | NA (abstract) | 0                | 110          | VisionScope Imaging System | Meniscal tear  |
| Gill et al. <sup>21</sup> (2018)       | A prospective, blinded, multicenter clinical trial to compare the efficacy, accuracy, and safety of in-office diagnostic arthroscopy with magnetic resonance imaging and surgical diagnostic arthroscopy | II                  | 23            | 0                | 110          | VisionScope Imaging System | Meniscal tear, osteoarthritis  |
| Ike and O'Rourke <sup>22</sup> (1995)  | Compartment-directed physical examination of the knee can predict articular cartilage abnormalities disclosed by needle arthroscopy  | IV                  | 9             | 0                | 20           | NR                         | Osteoarthritis   |
| Ike and O'Rourke <sup>23</sup> (1993)  | Detection of intraarticular abnormalities in osteoarthritis of the knee. A pilot study comparing needle arthroscopy with standard arthroscopy  | IV                  | 10            | 0                | 10           | NR                         | Meniscal tear, osteoarthritis, synovial abnormalities  |
| O'Rourke and Ike <sup>24</sup> (1994)  | Diagnostic arthroscopy in the arthritis patient  | IV                  | 6             | 0                | 1            | NR                         | Osteoarthritis   |
| Voigt et al. <sup>13</sup> (2014)*     | Diagnostic needle arthroscopy and the economics of improved diagnostic accuracy: A cost analysis   | III (cost analysis) | 9             | 0                | 1,397,304    | VisionScope Imaging System | Meniscal tear  |
| Voigt et al. <sup>12</sup> (2014)*     | In-office diagnostic arthroscopy for knee and shoulder intra-articular injuries its potential impact on cost savings in the United States  | III (cost analysis) | 9             | 429,502          | 972,326      | VisionScope Imaging System | Rotator cuff tear, medial meniscal tear  |
| West and Amin <sup>25</sup> (2017)     | In-office arthroscopy for the evaluation of chronic knee pain: A case report   | IV                  | 10            | 0                | 1            | mi-eye 2                   | Meniscal tear, osteoarthritis  |
| Deirmengian et al. <sup>9</sup> (2018) | Use of a small-bore needle arthroscope to diagnose intra-articular knee pathology: comparison with magnetic resonance imaging  | II                  | 20            | 0                | 106          | mi-eye 2                   | Meniscal tear, osteoarthritis, intra-articular loose body, osteochondritis dissecans, ACL tear |
| Chapman and Amin <sup>10</sup> (2018)  | The benefits of an in-office arthroscopy in the diagnosis of unresolved knee pain  | IV                  | 10            | 0                | 1            | mi-eye 2                   | Meniscal tear, ACL tear, osteochondral defect  |

NOTE. All studies investigated either shoulder pathology or knee pathology or investigated a combination thereof. The pathologies investigated were limited to meniscal tears (medial and lateral), osteoarthritis, synovitis, and rotator cuff tears in the included studies. Of the studies, 5 used the VisionScope Imaging System and 3 used the mi-eye 2 system as the choice of needle arthroscope, with the remaining 3 not specifying the make and model of scope.

ACL, anterior cruciate ligament; MINORS, Methodological Index for Non-randomized Studies; NA, not applicable; NR, not reported.

\*Data used from calendar years 2010 and 2013.

## Comparisons and Interpretation

Comparisons of percentage agreement, as reported using the  $\kappa$  statistic, between individual diagnostic modalities were conducted in 5 studies. Comparison of IONA to arthroscopy was performed in 5 studies; MRI to arthroscopy, in 4; and IONA to MRI, in 2.<sup>9,12,13,20,21,23</sup> Across 6 studies (248 patients), IONA and arthroscopy results were interpreted by the same orthopaedic surgeon. In 3 studies specifying the interpreting physician for MRI scans, the findings were interpreted by musculoskeletal radiologists in 2 studies (216 patients) and by the treating orthopaedic surgeon in 1 study (1 patient). The magnet strength for the MRI system was specified in 1 study (110 patients), at 1.5 T, and no magnetic resonance arthrograms were used across included studies.

## Pathologies Investigated

Diagnostic accuracy was stratified by pathology in 8 clinical studies and abstracts, with 5 studies (338 patients) including knee meniscal tears; 6 (248 patients), knee osteoarthritis; 2 (107 patients), anterior cruciate ligament (ACL) tears; 2 (107 patients), osteochondral defects; and 1 (10 patients), knee synovitis.<sup>9,10,19-21,23-25</sup> Specific pathologies were also described in the 2 cost analyses, with both including knee meniscal tears and 1 including rotator cuff tears<sup>12,13</sup> (Table 1).

Percentage agreement for the diagnosis of meniscal tears relative to arthroscopy was evaluated in 6 studies (336 patients), ranging from 76.6% to 100% for IONA and from 13.0% to 86.3% for MRI.<sup>9,12,13,20,21,23</sup> Of the 2 studies comparing agreement between MRI and IONA, 1 described agreement ranging from 11.2% to 54.6% across all meniscal tears.<sup>20</sup> The other study reported separate degrees of agreement for lateral (47.9%) and medial (42.9%) meniscal tears.<sup>21</sup> Diagnostic accuracy relative to arthroscopy for meniscal tears was evaluated in 5 studies (226 patients).<sup>9,12,13,21,23</sup> The sensitivity of IONA ranged from 90.5% to 100%, and that of MRI ranged from 59.5% to 91.4%. The specificity of IONA ranged from 93.1% to 100%, and that of MRI ranged from 82.9% to 100%. The positive predictive value (PPV) and negative predictive value (NPV) were reported in 4 studies, ranging from 90.5% to 100% and from 88.2% to 93.2%, respectively, for IONA and from 75.9% to 98.6% and from 76.3% to 93.1%, respectively, for MRI<sup>9,12,13,21</sup> (Table 2).

Percentage agreement for grading of osteoarthritis relative to arthroscopy was evaluated in 3 studies (248 patients), ranging from 71% to 90.2% for IONA and from 30.3% to 85.9% for MRI.<sup>9,21,23</sup> One study evaluating agreement between IONA and MRI for patellofemoral arthritis reported 52.8% agreement.<sup>21</sup> Diagnostic accuracy relative to arthroscopy for grading

of osteoarthritis was evaluated in 3 studies (226 patients).<sup>9,21,23</sup> The sensitivity of IONA ranged from 78.8% to 96.1%, and that of MRI ranged from 38.8% to 78.8%. The specificity of IONA ranged from 94.1% to 100%, and that of MRI ranged from 89.0% to 100%. The PPV and NPV were reported in 2 studies (216 patients), ranging from 81.8% to 100% and from 84.9% to 97.8%, respectively, for IONA, and from 76.5% to 96.3% and from 84.9% to 96.0%, respectively, for MRI<sup>9,21</sup> (Table 2).

Percentage agreement for the diagnosis of ACL insufficiency relative to arthroscopy was reported in 1 study (106 patients) as 100% for IONA and 91.6% for MRI.<sup>9</sup> Diagnostic accuracy relative to arthroscopy for ACL tears was reported in 1 study (106 patients).<sup>9</sup> The sensitivity of IONA was 100%, and that of MRI was 87.5%.<sup>9</sup> The specificity of IONA was 100%, and that of MRI was 96.7%. The PPV and NPV were reported in 1 study (106 patients) as 100% and 100%, respectively, for IONA and 82.4% and 97.8%, respectively, for MRI (Table 2).

Percentage agreement for the diagnosis of osteochondral defects relative to arthroscopy was reported in 1 study (106 patients) as 98.1% for IONA and 91.6% for MRI.<sup>9</sup> Diagnostic accuracy relative to arthroscopy for osteochondral defects was reported in 1 study (106 patients).<sup>9</sup> The sensitivity of IONA was 80%, and that of MRI was 50%. The specificity of IONA was 100%, and that of MRI was 95.9%. The PPV and NPV were reported in 1 study (106 patients) as 100% and 98.0%, respectively, for IONA and 55.6% and 94.9%, respectively, for MRI<sup>9</sup> (Table 2).

Percentage agreement for the diagnosis of intra-articular loose bodies relative to arthroscopy was reported in 1 study (106 patients) as 98.0% for IONA and 88.2% for MRI.<sup>9</sup> Diagnostic accuracy relative to arthroscopy for intra-articular loose bodies was reported in 1 study (106 patients).<sup>9</sup> The sensitivity of IONA was 86.5%, and that of MRI was 20%. The specificity of IONA was 100%, and that of MRI was 100%. The PPV and NPV were reported in 1 study (106 patients) as 100% and 97.8%, respectively, for IONA and 100% and 87.9%, respectively, for MRI<sup>9</sup> (Table 2).

Percentage agreement for the diagnosis of rotator cuff tears relative to arthroscopy was reported in 1 cost analysis as 88.5% for MRI.<sup>12</sup> Diagnostic accuracy relative to arthroscopy for rotator cuff tears was reported in 1 cost analysis for MRI, with sensitivity reported as 85.5% and specificity, 90.4% (Table 2).<sup>12</sup> Diagnostic accuracy of IONA relative to arthroscopy for knee synovitis was reported in 1 study (10 patients), with sensitivity of 71.0% and specificity of 100% (Table 2).<sup>23</sup>

## Relative Costs

The cost savings of IONA relative to MRI as a diagnostic modality were evaluated in 3 studies comprising

**Table 2.** Diagnostic Accuracy of Individual Diagnostic Modalities Used

| Authors                                | Title  | Diagnostic Accuracy of Needle Arthroscopy vs Standard Arthroscopy  | Diagnostic Accuracy of MRI vs Standard Arthroscopy   | Diagnostic Accuracy of Needle Arthroscopy vs MRI   |
|--|--|--|--|--|
| Xerogeanes et al. <sup>20</sup> (2015) | A prospective multi-center clinical trial to compare efficiency, accuracy and safety of the Visionscope imaging system compared to MRI and diagnostic arthroscopy  | 76.6%-90.2% agreement  | 13.0%-53.5% agreement  | 11.2%-54.6% agreement  |
| Ike and O'Rourke <sup>23</sup> (1993)  | Detection of intraarticular abnormalities in osteoarthritis of the knee. A pilot study comparing needle arthroscopy with standard arthroscopy  | Meniscal tear: 90% sensitivity, 100% specificity, 100% agreement<br>Osteoarthritis: 89% sensitivity, 100% specificity, 71% agreement<br>Synovitis: 71% sensitivity, 100% specificity, 36% agreement  | NR   | NR   |
| Voigt et al. <sup>13</sup> (2014)      | Diagnostic needle arthroscopy and the economics of improved diagnostic accuracy: A cost analysis*  | Medial meniscus: 98.6% PPV, 88.2% NPV, 94.4% sensitivity, 96.7% specificity, 93.2% agreement<br>Lateral meniscus: 90.5% PPV, 93.1% NPV, 90.5% sensitivity, 93.1% specificity, 92.0% agreement  | Medial meniscus: 78.8% PPV, 64.7% NPV, 81.3% sensitivity, 61.1% specificity, 74% agreement<br>Lateral meniscus: 69.0% PPV, 85.5% NPV, 66.7% sensitivity, 86.4% specificity, 80.3% agreement  | NR   |
| Voigt et al. <sup>12</sup> (2014)      | In-office diagnostic arthroscopy for knee and shoulder intra-articular injuries its potential impact on cost savings in the United States†   | NR   | Medial meniscus: 83.2% PPV, 90.1% NPV, 91.4% sensitivity, 81.1% specificity, 86.3% agreement<br>Rotator cuff tear: 84.7% PPV, 91.0% NPV, 85.5% sensitivity, 90.4% specificity, 88.5% agreement   | NR   |
| Gill et al. <sup>21</sup> (2018)       | A prospective, blinded, multicenter clinical trial to compare the efficacy, accuracy, and safety of in-office diagnostic arthroscopy with magnetic resonance imaging and surgical diagnostic arthroscopy | Medial femoral cartilage: 94.2% PPV, 96.0% NPV, 96.1% sensitivity, 94.1% specificity, 90.2% agreement<br>Medial tibial cartilage: 87.5% PPV, 95.7% NPV, 87.5% sensitivity, 95.7% specificity, 83.2% agreement<br>Medial meniscus: 98.6% PPV, 88.2% NPV, 94.4% sensitivity, 96.7% specificity, 88.8% agreement<br>Lateral femoral cartilage: 81.8% PPV, 94.8% NPV, 81.8% sensitivity, 94.8% specificity, 76.6% agreement<br>Lateral tibial cartilage: 95.0% PPV, 84.9% NPV, 82.6% sensitivity, 95.7% specificity, 78.5% agreement<br>Lateral meniscus: 90.5% PPV, 93.1% NPV, 90.5% sensitivity, 93.1% specificity, 83.6% agreement<br>Patellofemoral cartilage: 96.3% PPV, 87.9% NPV, 78.8% sensitivity, 98.1% specificity, 79.5% agreement | Medial femoral cartilage: 85.5% PPV, 65.9% NPV, 75.8% sensitivity, 78.4% specificity, 52.2% agreement<br>Medial tibial cartilage: 80.0% PPV, 59.7% NPV, 40.8% sensitivity, 89.6% specificity, 30.3% agreement<br>Medial meniscus: 78.8% PPV, 64.7% NPV, 81.3% sensitivity, 61.1% specificity, 42.9% agreement<br>Lateral femoral cartilage: 74.2% PPV, 73.4% NPV, 57.5% sensitivity, 85.5% specificity, 44.3% agreement<br>Lateral tibial cartilage: 76% PPV, 55.9% NPV, 38.8% sensitivity, 86.4% specificity, 24.5% agreement<br>Lateral meniscus: 69.0% PPV, 85.1% NPV, 66.7% sensitivity, 86.4% specificity, 53.5% agreement<br>Patellofemoral cartilage: 88.6% PPV, 61.4% NPV, 69.6% sensitivity, 84.4% specificity, 50.0% agreement | Medial femoral cartilage: 54.6% agreement<br>Medial tibial cartilage: 33.0% agreement<br>Medial meniscus: 42.9% agreement<br>Lateral femoral cartilage: 11.2% agreement<br>Lateral tibial cartilage: 24.5% agreement<br>Lateral meniscus: 47.9% agreement<br>Patellofemoral cartilage: 52.8% agreement |
| Deirmengian et al. <sup>9</sup> (2018) | Use of a small-bore needle arthroscope to diagnose intra-articular knee pathology:   | Medial meniscal tear: 100% PPV, 92.1% NPV, 95.8% sensitivity, 100% specificity, 97.2% agreement<br>Lateral meniscal tear: 100% PPV, 93.2% NPV, 86.5% sensitivity, 100% specificity, 95.3% agreement  | Medial meniscal tear: 91.2% PPV, 76.3% NPV, 87.3% sensitivity, 82.9% specificity, 85.9% agreement<br>Lateral meniscal tear: 75.9% PPV, 80.5% NPV,  |  |

(continued)

**Table 2.** Continued

| Authors | Title                                      | Diagnostic Accuracy of Needle Arthroscopy vs Standard Arthroscopy  | Diagnostic Accuracy of MRI vs Standard Arthroscopy   | Diagnostic Accuracy of Needle of Needle Arthroscopy vs MRI |
|---------|--|--|--|--|
|         | Comparison with magnetic resonance imaging | Intra-articular loose body: 100% PPV, 97.8% NPV, 86.7% sensitivity, 100% specificity, 98.0% agreement<br>Osteoarthritis: 100% PPV, 97.3% NPV, 93.9% sensitivity, 100% specificity, 98.1% agreement<br>Osteochondritis dissecans: 100% PPV, 98.0% NPV, 80% sensitivity, 100% specificity, 98.1% agreement<br>ACL tear: 100% PPV, 100% NPV, 100% sensitivity, 100% specificity, 100% agreement | 59.5% sensitivity, 89.9% specificity, 79.3% agreement<br>Intra-articular loose body: 100% PPV, 87.9% NPV, 20% sensitivity, 100% specificity, 88.2% agreement<br>Osteoarthritis: 76.5% PPV, 90.3% NPV, 78.8% sensitivity, 89.0% specificity, 85.9% agreement<br>Osteochondritis dissecans: 55.6% PPV, 94.9% NPV, 50% sensitivity, 95.9% specificity, 91.6% agreement<br>ACL tear: 82.4% PPV, 97.8% NPV, 87.5% sensitivity, 96.7% specificity, 95.3% agreement |  |

NOTE. Agreement was defined as concordance between diagnostic modalities for identification and, if applicable, grading of pathology specified. PPV, NPV, sensitivity, and specificity for both MRI and needle arthroscopy were obtained from literature values in appropriate studies.

ACL, anterior cruciate ligament; MRI, magnetic resonance imaging; NPV, negative predictive value; NR, not reported; PPV, positive predictive value.

\*Data used from calendar years 2010 and 2013.

†Data used from calendar year 2012.

1 abstract and 2 cost analyses.<sup>12,13,24</sup> The included abstract reported savings of \$1,028 per patient for use of IONA over MRI in the diagnosis of shoulder and knee pathology, although specific conditions and cost breakdowns were not specified in this study<sup>19</sup> (Table 3).

Two studies were cost analyses that used cost data for a given calendar year based on a predetermined diagnostic and treatment algorithm for MRI and then extrapolated these data to project IONA costs in place of MRI based on literature values of diagnostic accuracy.<sup>12,13</sup> Total costs calculated in these studies comprised the sum of costs for orthopaedic consultation, appropriate diagnostic evaluation (plain radiographs in addition to either MRI or IONA), and treatment based on findings (operative or conservative management). Both studies investigated medial meniscal tear diagnosis and treatment, with total costs per patient ranging from \$2,541 to \$2,871 for IONA and from \$3,026 to \$3,575 for MRI. This translated into overall cost savings ranging from \$171 to \$184 per patient for IONA relative to MRI. Treatment in both studies assumed a combination of arthroscopic meniscectomy and orthopaedic follow-up for positive findings and a combination of 2 weekly physiotherapy sessions over a 6-week period and orthopaedic follow-up for negative findings (Table 3).

Relative costs for the diagnosis and subsequent treatment of lateral meniscal tears using MRI or IONA were reported in 1 cost analysis.<sup>13</sup> Overall costs per patient were reported as \$2,198 and \$2,132 for IONA and MRI, respectively. This translated into a relative cost increase of \$66 per patient for use of IONA compared with MRI (Table 3).

Relative costs for the diagnosis and subsequent treatment of rotator cuff tears between MRI and IONA were reported in the remaining cost analysis.<sup>12</sup> Overall costs per patient were reported as \$3,290 and \$3,118 for MRI and IONA, respectively. This translated into cost savings of \$172 per patient for use of IONA compared with MRI (Table 3).

**Complications**

Projected complications of IONA along with associated costs were reported in the 2 cost analyses.<sup>12,13</sup> The complication rate of IONA was assumed to be approximately half that of knee arthroscopy in 1 study because only 1 portal site was used,<sup>13</sup> and it was assumed to be similar to that of shoulder or knee arthrocentesis in another study because a similar caliber of needle was used in both interventions.<sup>12</sup> Estimates for the former study were as follows: 0.15% rate of reoperation for any cause, 0.095% rate of venous thromboembolism, 0.06% rate of deep vein thrombosis, and 0.005% rate of infection.<sup>13</sup> The costs of these complications per patient were estimated at

**Table 3.** Cost Comparisons Between Use of Needle Arthroscopy or MRI for Diagnosis of Various Conditions in Shoulder or Knee

| Authors                               | Title  | Cost Parameter, \$                                   |  |  |  | Savings of Using VSI Over MRI per Patient |
|---------------------------------------|--|--|--|--|--|---|
|                                       |  | Cost per Patient                                     | Cost per Complication                          | Total Cost   | Cost Difference  |   |
| Voigt et al. <sup>13</sup> (2014)     | Diagnostic needle arthroscopy and the economics of improved diagnostic accuracy: A cost analysis*  | MMT with MRI: 3,575 (community) and 3,529 (academic) | MMT with MRI: 72 (community) and 72 (academic) | MMT with MRI: 2,718 million (community) and 2,682 million (academic) |  |   |
|                                       |  | MMT with VSI: 3,342 (community) and 3,365 (academic) | MMT with VSI: 45 (community) and 43 (academic) | MMT with VSI: 2,541 (community) and 2,559 (academic)                 | MMT (MRI vs VSI): -177 million (community) and -115 million (academic) |   |
|                                       |  | LMT with MRI: 2,087 (community) and 2,132 (academic) | LMT with MRI: 72 (community) and 72 (academic) | LMT with MRI: 1,329 (community) and 1,358 (academic)                 |  |   |
|                                       |  | LMT with VSI: 2,110 (community) and 2,285 (academic) | LMT with VSI: 40 (community) and 39 (academic) | LMT with VSI: 1,343 (community) and 1,455 (academic)                 | LMT (MRI vs VSI): +14 million (community) and +95 million (academic)   |   |
| Voigt et al. <sup>12</sup> (2014)     | In-office diagnostic arthroscopy for knee and shoulder intra-articular injuries its potential impact on cost savings in the United States† | MMT with SOC: 3,026                                  | MMT with SOC: 72                               | MMT with SOC: 2,943 million  |  |   |
|                                       |  | MMT with VSI: 2,871                                  | MMT with VSI: 43                               | MMT with VSI: 151 million  | MMT (SOC vs VSI): 151 million  |   |
|                                       |  | RCT with SOC: 3,290                                  | RCT with SOC: 146                              | RCT with SOC: 1,438  |  |   |
|                                       |  | RCT with VSI: 3,118                                  | RCT with VSI: 92                               | RCT with VSI: 1,379  | RCT (SOC vs VSI): 59   |   |
| Gill and Carroll <sup>19</sup> (2013) | Cost-effective in-office diagnostic imaging: Visionscope versus MRI  |  |  |  |  | 1,028                                     |

NOTE. Overall costs were calculated using cost data from the calendar year from which the volume of conducted procedures was extracted, in conjunction with literature values of diagnostic accuracy for MRI and/or needle arthroscopy relative to standard diagnostic arthroscopy. On the basis of whether a diagnostic procedure was projected to produce a positive or negative result for a given pathology, a standardized treatment algorithm was followed involving combinations of further diagnostic procedures, operative intervention, and conservative management to calculate costs per patient.

LMT, lateral meniscal tear; MMT, medial meniscal tear; MRI, magnetic resonance imaging; RCT, rotator cuff tear; SOC, standard of care; VSI, VisionScope Imaging System.

\*Data used from calendar years 2010 and 2013.

†Data used from calendar year 2012.



\$44 for the diagnosis of medial meniscal tears and \$39.50 for the diagnosis of lateral meniscal tears. In the latter study, projected complications included reoperation for any cause at a rate of 0.01%. The costs of said complications per patient were projected at \$43 for use in the diagnosis of medial meniscal tears and \$92 for use in the diagnosis of rotator cuff tears.<sup>12</sup> Across the remaining studies, there were no reports of complications or adverse events associated with IONA use (Table 4).

### Patient-Reported Outcomes

All clinical studies reported good patient tolerance of IONA. However, across included studies, no data on subjective patient experience or perceptions regarding IONA were reported.

### Discussion

The key findings of this systematic review are that, in terms of percentage agreement with and diagnostic accuracy compared with arthroscopy, IONA is comparable or potentially superior to intermediate-field MRI for knee osteoarthritis across all compartments, medial and lateral meniscal tears, ACL insufficiency, and intra-articular loose bodies. However, this modality is likely inferior or lacks adequate evidence in comparison to MRI for the diagnosis of osteochondral defects and rotator cuff tears. Preliminary cost analyses suggest that IONA may provide cost savings compared with MRI for the workup of medial meniscal tears and rotator cuff tears but not lateral meniscal tears. Finally, no major or minor complications or adverse events are reported with the use of this minimally invasive technique. As such, there is literature support, albeit limited, for the use of IONA in the diagnosis and characterization of certain knee pathologies.

Although this review did aim to identify current indications for IONA use, the scope of the current literature is quite narrow, with only 1 study commenting on use in the shoulder and most studies focusing on meniscal tears and osteoarthritis of the knee. This creates substantial difficulty in commenting on the utility of IONA for other conditions within the knee and, even more so, other joints. This narrow scope may be related to the impracticality of IONA in deeper joints requiring manipulation such as the shoulder and hip.<sup>26,27</sup>

The apparently promising results of existing cost analyses of IONA use should be considered quite preliminary, owing to limited published data on diagnostic accuracy of IONA and thus uncertainty in the validity of these apparently lower costs. Furthermore, although there are absolute monetary cost savings described in both cost analyses, it is difficult to evaluate whether these savings are substantial enough to justify replacing MRI with IONA use in this context or other health care systems. Despite IONA often being touted to provide

time savings and reductions in patient stress, no formal investigations have been performed to date regarding patient experience and satisfaction with the use of IONA or whether the technology expedites time to surgery.<sup>10,25</sup> These shortcomings are unavoidable until other health technology analyses can be performed, evaluating the relative impact of IONA on health care—associated costs, patient productivity, and quality-adjusted life-years.

Beyond the features highlighted in this review, IONA has several practical aspects that may facilitate the workup of joint-related pain. A shortcoming of the high level of imaging detail provided by MRI is the degree of false-positive results in musculoskeletal pathology.<sup>28-33</sup> These confounding findings may result in overtreatment decisions.<sup>10,31</sup> The similarity between views obtained in IONA and arthroscopy allows for the development of an operative plan with greater certainty, with potential cost savings derived from decreased complication rates and operative times.<sup>12,13</sup> In conjunction with diagnostic intra-articular injections of local anesthetic, IONA allows for direct visualization of injectate, minimizing the possibility of false-positive results due to periarticular injection.<sup>34-37</sup> Previous studies have supported the utility of second-look arthroscopy as a superior tool to postoperative MRI in the evaluation of ligamentous, meniscal, or chondral healing after repair and/or graft transplantation.<sup>38-41</sup> Should the views obtainable in IONA truly parallel those obtained in the operating room, the procedure offers an alternative to second-look arthroscopy in these scenarios while avoiding the risks associated with a repeated operation.<sup>42</sup> Finally, patients with contraindications to MRI, including the presence of aneurysm clips or implanted pacemakers and/or claustrophobia, are offered an alternative modality boasting comparable diagnostic value in the form of IONA.<sup>5</sup>

The established role of MRI in diagnostic algorithms for joint pathology is a significant barrier to routine use of IONA.<sup>1,2,4,6</sup> The indications, contraindications, and complication profiles of the use of IONA in musculoskeletal pathology are either poorly established or absent in the literature. Although our review does discuss the comparable diagnostic value of IONA to arthroscopy, neither holds the ability to evaluate extra-articular structures that may also be contributing to disease. This is of importance for patients with concomitant intra-articular and periarticular soft-tissue pathology, with lack of recognition of the former leading to inappropriate prioritization and overall management of the pathologies as a whole. The indispensability of MRI in such scenarios further limits the number of situations in which the use of IONA alone may be sufficient to establish an adequate management plan.

Although IONA has been touted to provide similar diagnostic information to arthroscopy, the differences

**Table 4.** Complications, Incidence, and Associated Costs of Management

| Authors                              | Title  | Complications, Incidence, and Cost   |  |   |
|--------------------------------------|--|--|--|---|
|                                      |  | Diagnostic Knee Arthroscopy  | Diagnostic Shoulder Arthroscopy  | Needle Arthroscopy  |
| Voigt et al. <sup>13</sup><br>(2014) | Diagnostic needle arthroscopy and the economics of improved diagnostic accuracy: A cost analysis <sup>a</sup>  | Reoperation: 0.30% (3/1,000)<br>Lavage and drainage: \$521.91-\$2,111.62<br>VTE: 0.19% (1.9/1,000)<br>12 mo txt: \$14,865<br>DVT: 0.12% (1.2/1,000)<br>12 mo txt: \$14,865<br>PE: 0.08% (0.8/1,000)<br>12 mo txt: \$22,900 | NR   | Reoperation: 0.25% (2.5/1,000)<br>Lavage and drainage: \$521.91-\$2,111.62<br>VTE: 0.95% (0.95/1,000)<br>12 mo txt: \$14,865<br>DVT: 0.06% (0.6/1,000)<br>12 mo txt: \$14,865<br>PE: 0.04% (0.4/1,000)<br>12 mo txt: \$22,900 |
| Voigt et al. <sup>12</sup><br>(2014) | In-office diagnostic arthroscopy for knee and shoulder intra-articular injuries its potential impact on cost savings in the United States <sup>†</sup> | Reoperation: 0.30% (3/1,000)<br>Lavage and drainage: \$521.91-\$2,111.62<br>VTE: 0.19% (1.9/1,000)<br>12 mo txt: \$14,865<br>DVT: 0.12% (1.2/1,000)<br>12 mo txt: \$14,865<br>PE: 0.08% (0.8/1,000)<br>12 mo txt: \$22,900 | VTE: 0.038% (0.4/1,000)<br>12 mo txt: \$14,865<br>DVT: 0.029% (0.3/1,000)<br>12 mo txt: \$14,865<br>PE: 0.01% (0.2/1,000)<br>12 mo txt: \$22,900<br>Arthrofibrosis: 1% (10/1,000)<br>Lysis of adhesions: \$594.38-\$3,880.22<br>Repeated surgical intervention: 0.6% (6/1,000)<br>Rotator cuff repair: \$1,086.35-\$3,880.22<br>Deep infection: 0.2% (2/1,000)<br>Postoperative infection txt: \$5,665<br>Biceps tendon rupture: 0.2% (2/1,000)<br>Major shoulder or elbow procedure: \$11,621 | Reoperation: 0.01% (1/10,000)<br>Lavage and drainage: \$521.91-\$2,111.62   |

NOTE. Literature values for complication rates are listed for each diagnostic modality used. Costs are based on the recommended treatment protocol for each complication for a given calendar year.

DVT, deep vein thrombosis; NR, not reported; PE, pulmonary embolism; txt, treatment; VTE, venous thromboembolism.

<sup>a</sup>Data from calendar years 2010 and 2013 were used. The complication rate of needle arthroscopy was assumed to be approximately half that of diagnostic knee arthroscopy because of the use of only 1 port compared with 2 ports.

<sup>†</sup>Data from calendar year 2012 were used. The rates of complications seen in needle arthroscopy were assumed to be approximately half that of rates seen in arthrocentesis, with an identical complication profile. This assumption was made due to the two procedures utilizing similar technique and calibre of needle.

in tools and conditions between IONA and arthroscopy make obtaining adequate visualization more challenging with the former. IONA lacks variability in scope length and angle compared with arthroscopy, which limits its ability to acquire an adequate view in patients of varying body habitus and in joints difficult to assess with a 0° camera.<sup>43-46</sup> Although IONA is capable of navigating smaller joint spaces at baseline, navigation of degenerative and deformed joints may prove more challenging without the tools and assisted devices available during arthroscopic surgery.<sup>11,42,47,48</sup> The ability to manipulate intra-articular elements during arthroscopy is invaluable in characterizing dynamic lesions and navigating potential obstructions such as with a bucket-handle meniscal tear.<sup>48-50</sup> Finally, because IONA is conducted with local anesthetic alone, options to improve visualization during the procedure, including altering intraoperative blood pressure, performing joint manipulation, and altering the degree of joint distension, are not practical.<sup>43,51,52</sup>

Despite IONA's theoretical similarities to arthroscopy, its implementation as a technology does necessitate substantial training and financial investment. In particular, the amount of training required, learning curve of the technology, and sources of financial coverage for the patient require further exploration in the context of IONA. Overall, a combination of increased costs to the surgeon, logistic uncertainties, lack of widespread availability, and previously described technical limitations contribute to limited acceptance of this modality in its current state.

### Limitations

The findings of this review supporting the benefits and utility of IONA should be interpreted with caution because of the limited scope, heterogeneous reporting among studies, and overall low quality of evidence. Furthermore, the limited population sizes of most studies currently in the literature, coupled with a lack of prospective and comparative studies, make for difficulty in establishing substantial conclusions or recommendations. Although minimal complications were projected by the included cost analyses, the small sample sizes of the clinical studies in this review necessitate further exploration of complication rates with use of IONA. One of the main concerns regarding the reported diagnostic accuracy of IONA throughout this review is the risk of confirmation bias with a single reader for both IONA and arthroscopy, which was the case in all included clinical studies. This is compounded by the fact that MRI scans in most included studies were read by a separate physician, likely contributing to the relatively lower reported diagnostic accuracy and low degree of agreement. Objective evaluation of such results will be crucial in future studies to fully elucidate the relative utility of IONA as a diagnostic tool. Moreover,

variability in the quality of MRI studies exists based on the presence of intra-articular contrast, as well as magnet strength, which—although not explored in this review—are critical factors to consider in comparing the diagnostic utility of IONA relative to MRI.<sup>53</sup> Notably, the current literature does not report on patient expectations and perspectives surrounding the use of IONA. Given the invasiveness of this technology relative to imaging procedures, patient buy-in is certainly an area requiring exploration in future studies. Ultimately, these methodologic oversights in the current body of literature likely lend to an overstatement of the potential diagnostic value of IONA—at least in these early stages.

### Conclusions

IONA holds potential for cost savings and improved diagnostic accuracy relative to MRI, primarily for intra-articular meniscal, ligamentous, and chondral defects of the knee. However, its current indications for use in other joints are limited to rotator cuff tears in the shoulder, making its diagnostic value in other joints much more limited. The current quality and breadth of evidence are significantly lacking, with numerous practical shortcomings. To improve acceptance of IONA, priority should be placed on establishing defined protocols, indications, contraindications, and patient perspectives for the procedure.

### References

1. Momenzadeh O, Gerami M, Sefidbakht S, Dehghani S. Assessment of correlation between MRI and arthroscopic pathologic findings in the shoulder joint. *Arch Bone Jt Surg* 2015;3:286-290.
2. Shaw P, Jain L, Gupta N. Sensitivity and specificity of MRI in detecting meniscal tears, confirmed subsequently with arthroscopy. *Int J Orthop Sci* 2017;3:838-840.
3. McMillan S, Schwartz M, Jennings B, Faucett S, Owens T, Ford E. In-office diagnostic needle arthroscopy: Understanding the potential value for the US healthcare system. *Am J Orthop (Belle Mead NJ)* 2017;46:252-256.
4. Pompan DC. Appropriate use of MRI for evaluating common musculoskeletal conditions. *Am Fam Physician* 2011;83:883-884.
5. Tsai LL, Grant AK, Morteale KJ, Kung JW, Smith MP. A practical guide to MR imaging safety: What radiologists need to know. *Radiographics* 2015;35:1722-1737.
6. Dean Deyle G. The role of MRI in musculoskeletal practice: A clinical perspective. *J Man Manip Ther* 2011;19:152-161.
7. Health Quality Ontario. Time to patient's first orthopedic surgical appointment. Wait times for surgeries and procedures. Published 2018. <http://www.hqontario.ca/System-Performance/Wait-Times-for-Surgeries-and-Procedures/Wait-Times-for-Orthopedic-Surgeries-including-Hip-Replacement-and-Knee-Replacement/Time-to-Patients-First-Orthopedic-Surgical-Appointment>. Accessed June 24, 2018.

8. Health Quality Ontario. Time from decision to orthopedic surgery. Wait times for surgeries and procedures. Published 2018, <http://www.hqontario.ca/System-Performance/Wait-Times-for-Surgeries-and-Procedures/Wait-Times-for-Orthopedic-Surgeries-including-Hip-Replacement-and-Knee-Replacement/Time-from-Decision-to-Having-Orthopedic-Surgery>. Accessed June 24, 2018.
9. Deirmengian CA, Dines JS, Vernace JV, Schwartz MS, Creighton RA, Gladstone JN. Use of a small-bore needle arthroscope to diagnose intra-articular knee pathology: Comparison with magnetic resonance imaging. *Am J Orthop (Belle Mead NJ)* 2018;47.
10. Chapman GL, Amin NH. The benefits of an in-office arthroscopy in the diagnosis of unresolved knee pain. *Case Rep Orthop* 2018;2018:6125676.
11. Patel KA, Hartigan DE, Makovicka JL, Dulle DL, Chhabra A, Chhabra A. Diagnostic evaluation of the knee in the office setting using small-bore needle arthroscopy. *Arthrosc Tech* 2018;7:e17-e21.
12. Voigt JD, Mosier M, Huber B. In-office diagnostic arthroscopy for knee and shoulder intra-articular injuries its potential impact on cost savings in the United States. *BMC Health Serv Res* 2014;14:203.
13. Voigt JD, Mosier M, Huber B. Diagnostic needle arthroscopy and the economics of improved diagnostic accuracy: A cost analysis. *Appl Health Econ Health Policy* 2014;12: 523-535.
14. Liberati A, Altman DG, Tetzlaff J, et al. The PRISMA statement for reporting systematic reviews and meta-analyses of studies that evaluate healthcare interventions: Explanation and elaboration. *BMJ* 2009;339: b2700.
15. Shea BJ, Hamel C, Wells GA, et al. AMSTAR is a reliable and valid measurement tool to assess the methodological quality of systematic reviews. *J Clin Epidemiol* 2009;62: 1013-1020.
16. Slim K, Nini E, Forestier D, Kwiatkowski F, Panis Y, Chipponi J. Methodological index for non-randomized studies (Minors): Development and validation of a new instrument. *ANZ J Surg* 2003;73:712-716.
17. Schmidt AH, Zhao G, Turkelson C. Levels of evidence at the AAOS meeting: Can authors rate their own submissions, and do other raters agree? *J Bone Joint Surg Am* 2009;91:867-873.
18. Dhawan A, Brand JC, Provencher MT, Rossi MJ, Lubowitz JH. Research pearls: The significance of statistics and perils of pooling. *Arthroscopy* 2017;33:1099-1101.
19. Gill TJ, Carroll KM. Cost-effective in-office diagnostic imaging: Visionscope versus MRI. *Arthroscopy* 2013;29:e88 (suppl).
20. Xerogeanes JW, Safran MR, Huber B, Mandelbaum BR, Robertson W, Gambardella RA. A prospective multicenter clinical trial to compare efficiency, accuracy and safety of the VisionScope imaging system compared to MRI and diagnostic arthroscopy. *Orthop J Sport Med* 2014;2(suppl):2325967114S00100.
21. Gill TJ, Safran M, Mandelbaum B, Huber B, Gambardella R, Xerogeanes J. A prospective, blinded, multicenter clinical trial to compare the efficacy, accuracy, and safety of in-office diagnostic arthroscopy with magnetic resonance imaging and surgical diagnostic arthroscopy. *Arthroscopy* 2018;34:2429-2435.
22. Ike R, O'Rourke KS. Compartment-directed physical examination of the knee can predict articular cartilage abnormalities disclosed by needle arthroscopy. *Arthritis Rheum* 1995;38:917-925.
23. Ike RW, O'Rourke KS. Detection of intraarticular abnormalities in osteoarthritis of the knee. A pilot study comparing needle arthroscopy with standard arthroscopy. *Arthritis Rheum* 1993;36:1353-1363.
24. O'Rourke KS, Ike RW. Diagnostic arthroscopy in the arthritis patient. *Rheum Dis Clin North Am* 1994;20: 321-342.
25. West JA, Amin NH. In-office arthroscopy for the evaluation of chronic knee pain: A case report. *SAGE Open Med Case Rep* 2017;5:2050313X17740992.
26. Farmer KW, Wright TW. Shoulder arthroscopy: The basics. *J Hand Surg Am* 2015;40:817-821.
27. Stone AV, Howse EA, Mannava S, Miller BA, Botros D, Stubbs AJ. Basic hip arthroscopy: Diagnostic hip arthroscopy. *Arthrosc Tech* 2017;6:e699-e704.
28. Pfirrmann CWA, Zanetti M, Hodler J. Joint magnetic resonance imaging: Normal variants and pitfalls related to sports injury. *Radiol Clin North Am* 2002;40:167-180.
29. Elliott J, Flynn T, Al-Najjar A, Press J, Nguyen B, Noteboom JT. The pearls and pitfalls of magnetic resonance imaging for the spine. *J Orthop Sport Phys Ther* 2011;41:848-860.
30. Felix G, Setor De Radiologia M, Por D. Artifacts and pitfalls in shoulder magnetic resonance imaging. *Radiol Bras* 2015;48:242-248.
31. Ben-Galim P, Steinberg EL, Amir H, Ash N, Dekel S, Arbel R. Accuracy of magnetic resonance imaging of the knee and unjustified surgery. *Clin Orthop Relat Res* 2006;447:100-104.
32. Roy JS, Braën C, Leblond J, et al. Diagnostic accuracy of ultrasonography, MRI and MR arthrography in the characterisation of rotator cuff disorders: A systematic review and meta-analysis. *Br J Sports Med* 2015;49: 1316-1328.
33. Bhatnagar A, Bhonsle S, Mehta S. Correlation between MRI and arthroscopy in diagnosis of shoulder pathology. *J Clin Diagn Res* 2016;10:RC18-RC21.
34. Soh E, Li W, Ong KO, Chen W, Bautista D. Image-guided versus blind corticosteroid injections in adults with shoulder pain: A systematic review. *BMC Musculoskelet Disord* 2011;12:137.
35. Guerini H, Ayral X, Vuillemin V, et al. Ultrasound-guided injection in osteoarticular pathologies: General principles and precautions. *Diagn Interv Imaging* 2012;93:674-679.
36. Singh J, Khan WS, Marwah S, Wells G, Tannous DK, Sharma HK. Do we need radiological guidance for intra-articular hip injections? *Open Orthop J* 2014;8:114-117.
37. Malfair D. Therapeutic and diagnostic joint injections. *Radiol Clin North Am* 2008;46:439-453, v.
38. Yu M, Yu JK, Ao YF, Zheng ZZ, Gong X, Leung KKM. Diagnostic values of 3 methods for evaluating meniscal healing status after meniscal repair: Comparison among second-look arthroscopy, clinical assessment, and magnetic resonance imaging. *Am J Sports Med* 2011;39:735-742.

39. Ramappa AJ, Gill TJ, Bradford CH, Ho CP, Steadman JR. Magnetic resonance imaging to assess knee cartilage repair tissue after microfracture of chondral defects. *J Knee Surg* 2007;20:228-234.
40. Kim JM, Kim JM, Jeon BS, et al. Comparison of post-operative magnetic resonance imaging and second-look arthroscopy for evaluating meniscal allograft transplantation. *Arthroscopy* 2015;31:859-866.
41. Riyami M, Rolf C. Evaluation of microfracture of traumatic chondral injuries to the knee in professional football and rugby players. *J Orthop Surg Res* 2009;4:13.
42. McMillan S, Saini S, Alyea E, Ford E. Office-based needle arthroscopy: A standardized diagnostic approach to the knee. *Arthrosc Tech* 2017;6:e1119-e1124.
43. Lowe EB. Diagnostic and operative arthroscopy. *Surg Clin North Am* 1983;63:599-605.
44. Dienst M. Hip arthroscopy: Technique and anatomy. *Oper Tech Sports Med* 2005;13:13-23.
45. Stetson WB, Ferkel RD. Ankle arthroscopy: I. Technique and complications. *J Am Acad Orthop Surg* 1996;4:17-23.
46. Bedi A, Dines J, Dines DM, et al. Use of the 70° arthroscope for improved visualization with common arthroscopic procedures. *Arthroscopy* 2010;26:1684-1696.
47. Banks LN, Reuben SF. Knee arthroscopy: Viewing the posterior horn of the medial meniscus. *Ann R Coll Surg Engl* 2009;91:522.
48. Nakase J, Kitaoka K, Tsuchiya H. Arthroscopic resection of a bucket handle tear of the meniscus: A technical note. *J Orthop Surg* 2010;18:378-381.
49. Said HG, Goyal S, Fetih TN. Meniscus delivery: A maneuver for easy arthroscopic access to the posterior horn of the medial meniscus. *SICOT J* 2016;2:10.
50. Laffenêtre O. Osteochondral lesions of the talus: Current concept. *Orthop Traumatol Surg Res* 2010;96:554-566.
51. Burkhart SS, Danaceau SM, Athanasiou KA. Turbulence control as a factor in improving visualization during subacromial shoulder arthroscopy. *Arthroscopy* 2001;17:209-212.
52. Morrison DS, Schaefer RK, Friedman RL. The relationship between subacromial space pressure, blood pressure, and visual clarity during arthroscopic subacromial decompression. *Arthroscopy* 1995;11:557-560.
53. Shapiro L, Harish M, Hargreaves B, Staroswiecki E, Gold G. Advances in musculoskeletal MRI: Technical considerations. *J Magn Reson Imaging* 2012;36:775-787.