

Meniscal repair in anterior cruciate ligament reconstruction: a long-term outcome study

J. T. K. Melton · J. R. Murray · A. Karim ·
H. Pandit · F. Wandless · N. P. Thomas

Received: 6 December 2010 / Accepted: 21 March 2011 / Published online: 9 April 2011
© Springer-Verlag 2011

Abstract

Purpose To study the long-term outcome of patients who have undergone inside-out, vertical stacked mattress suture repair of meniscal tears combined with anterior cruciate ligament (ACL) reconstruction.

Methods From a database of ACL reconstructed patients, consecutive patients undergoing concomitant meniscal repair and ACL reconstruction between 1991 and 1999 were identified. Patients with previous ACL or meniscal pathology were excluded. Two age- and sex-matched cohorts who had undergone combined ACL reconstruction and meniscectomy and who had undergone ACL reconstruction with normal menisci were identified for comparison. Outcome scoring included IKDC and Lysholm scores for the meniscal repair group. Two sample *t*-tests and chi-square tests were used to compare the IKDC subjective scores, with a minimum level of significance set at 5% ($P = 0.05$).

Results Forty-four patients were identified for analysis with a median follow-up of 10 years (7.7–12.6). Patients undergoing ACL reconstruction combined with meniscal repair had a mean IKDC of 84.2 compared with a mean score of 70.5 ($P = 0.008$) in patients who had undergone meniscectomy and 88.2 ($P = 0.005$) in patients with intact menisci. 86.2% of patients with ACL reconstruction and meniscal repair had Lysholm score of between 80 and 100%. Sixty-nine percent follow-up was achieved. Survival analysis by life table method shows a best case of 89% 10-years survival.

Conclusions This study demonstrates that good long-term outcomes can be obtained in patients up to over 12 years after combined ACL reconstruction and meniscal repair. Improved functional scores can be achieved when compared with ACL reconstruction and meniscectomy. The authors advocate repair of meniscal tears during ACL reconstruction unless there is complex tearing, radial tearing or plastic deformation of the remaining meniscus.
Level of evidence III.

Keywords Meniscal repair · Anterior cruciate ligament · Reconstruction · Results · Long-term

Introduction

Healthy meniscal cartilage of the knee is involved in load transmission and joint stability, lubrication and nutrition of the articular cartilage. When damaged, these meniscal functions are impaired, predisposing to degenerative change within the joint [6]. Studies have demonstrated a 75% reduction in total contact area following medial and lateral total meniscectomy leading to an increase in peak tibio-femoral contact pressures of 235% [6, 13]. Reduced articular contact area impedes normal lubrication and synovial fluid nutrition of articular hyaline cartilage leading to premature joint degeneration. Advances in arthroscopic surgery over the last 25 years coupled with increasing understanding of meniscal function when intact, damaged or removed have led to a shift away from meniscal resection and towards meniscal preservation [29, 32, 40, 43]. Common meniscal preservation tactics include leaving stable or partial tears alone, limited partial meniscectomy and meniscal repair [9]. Pujol and Beaufils reviewed the evidence for meniscal preservation with and

J. T. K. Melton (✉) · J. R. Murray · A. Karim · H. Pandit ·
F. Wandless · N. P. Thomas
Trauma and Orthopaedics, North Hampshire Hospital,
Aldermaston Road, Basingstoke RG24 9NA, UK
e-mail: joelmelton@doctors.org.uk

without fixation of stable meniscal tears and found poor results when medial meniscal tears were left in situ without fixation [34]. Meniscal repair using either ‘all-inside’ or ‘inside out’ techniques has been shown to have high success rates in the short term, but there is less evidence to support long-term improved outcome [14].

The consequences of meniscectomy have been well discussed in the literature and recently reviewed by Amis and McDermott [4]. Partial meniscectomy is the mainstay of treatment for the majority of meniscal tears, but even partial meniscectomy has been linked to an increased incidence of degenerative change [26, 35]. More recently, there has been interest in meniscal transplantation to try and recreate the functions of the meniscus in the painful meniscus-deficient knee [25, 28]. The status of the meniscal cartilages in the context of anterior cruciate ligament (ACL) reconstruction has previously been shown to be an important predictor of the long-term development of osteoarthritis [24, 33].

The absence of a functioning ACL has now been accepted as a predisposing factor in the progression to degenerative joint disease after the inevitable symptomatic meniscal abnormalities occur [9, 31]. In addition, the menisci themselves are also known to contribute to knee stability, as secondary restraints [9]. Therefore, in the presence of a reconstructed ACL, a repaired meniscus may augment knee stability on account of its secondary restraint. Conversely, in the absence of a functioning meniscus, a worse outcome from ACL reconstruction might be expected due to the increased force per unit area on the articular surfaces [6].

In this study, the authors set out to investigate the long-term outcome of meniscal repair when performed with simultaneous ACL reconstruction. They compare this in a matched cohort study to ACL reconstruction with partial meniscectomy and ACL reconstruction with intact menisci. The null hypothesis was that there was no difference in long-term outcome between the three groups described.

Materials and methods

From an ACL reconstruction database (with prospective data collection), 44 patients (Group R) who had undergone simultaneous meniscal repair and ACL reconstruction between 1991 and 1999 were identified. Any patients who had undergone simultaneous treatment for chondral or osteochondral lesions were not included in the patient cohort. Of the 44 patients, 9 were excluded for previous meniscal or ACL surgery.

In order to identify the effects of a meniscal injury on the knee and any benefits associated with meniscal repair compared with partial meniscectomy at the time of ACL

reconstruction; two age- and sex-matched cohorts of 40 patients were selected from the prospective database, who had either undergone partial meniscectomy (Group M) at the time of surgery or who had normal menisci (Group N). Patients who had undergone simultaneous treatment for chondral or osteochondral lesions were not included in these patient cohorts. Patients in all three groups therefore had no chondral damage worse than minor grade II change.

All surgery was carried out arthroscopically by the senior author. Only menisci with bucket handle and peripheral tears without plastic deformation were repaired. The torn edges were routinely rasped in an attempt to ‘freshen’ the tissues to improve healing. Stacked vertical non-absorbable mattress sutures passed from inside to out were used for the repair. Radial tears, complex and degenerative tears were not repaired, but underwent partial meniscectomy. The ACL was reconstructed with either four-strand hamstring (HS) or Bone-Patellar Tendon-Bone (BTB) autografts.

The post-operative protocol included immediate weight bearing and was identical to the senior author’s usual ACL regime except that patients were instructed to avoid deep flexion (flexion beyond 100°) for the first 6 weeks.

Subjective and objective evaluation was performed on an annual basis from 1 year post-operatively on all patients. Subjective and objective components were assessed using a validated patient questionnaire: the International Knee Documentation Committee (IKDC) evaluation proforma [16], with scores from the most recent evaluation used in the analyses. To achieve the most up to date follow-up with least patient interference, we used the International Knee Documentation Committee (IKDC) scores, patients being contacted first by letter and then telephone call. Lysholm knee scores were also analysed for the study group.

Statistical analysis

Two sample *t*-tests and chi-square tests were used to compare the IKDC subjective scores, with a minimum level of significance set at 5% ($P = 0.05$). All statistical methods and calculations were checked and approved by an independent professional statistician.

Results

Follow-up ranged from 7.7 to 12.6 years (median 10 years). A total of 44 patients were identified for analysis with 9 patients excluded having had previous meniscal or cruciate surgery. Thirty-seven menisci in 35 patients were sutured. The median age at surgery in the meniscal repair group was 28 (range, 20–53). Eight cases underwent ACL

Table 1 Characteristics of patient group undergoing meniscal repair

Patient number	44		
After exclusions	35	21 Males	14 Females
Menisci sutured	37	2 Bilateral	
Age at surgery	28	Range 20–53	
Side	32 Medial	5 Lateral	2 Medial and lateral
Meniscal zone	22 White–white (Rim > 3 mm)	12 Red–white (Rim 1–3 mm)	3 Red–red (Rim 0–1 mm)
Timing	29 chronic (>3 months)	8 sub-acute (<3 months)	No acute cases
Number of sutures	Median = 4	Range = 1–9	SD = 1.7
ACL—patella tendon	31	Interference screws femur	Interference screws (26) langdanner (5) tibia
ACL—4 strand hamstring	4	Femoral anchors	Tibial Intrafix
Clinical review number	23 (66%) Patients	Mean f/u 5 year	1.1–7.7
Subjective IKDC and lysholm returns	24 (69%) Patients	Median f/u 10 year	Range 7.7–12.6

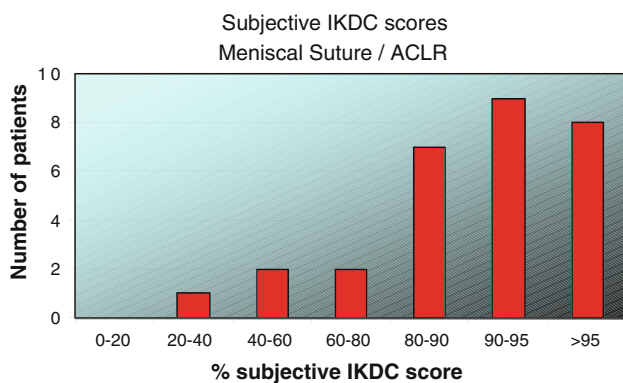


Fig. 1 Subjective IKDC scores for meniscal suture with ACL reconstruction

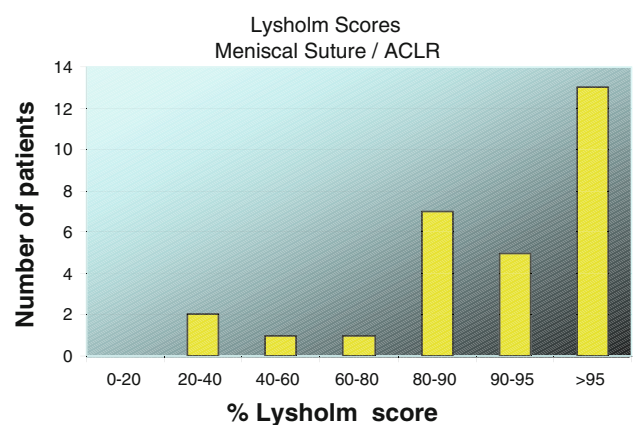


Fig. 2 Subjective Lysholm scores for meniscal suture with ACL reconstruction

reconstruction and meniscal repair within 3 months of injury, and 29 were operated on more than 3 months following injury. No patients were operated on acutely, within 6 weeks. Twenty-four patients were available for long-term follow-up. Demographics, nature of the meniscal injury and surgical repair are shown in Table 1. As a part of the prospective study, these patients were followed up with clinical review, including validated cruciometry (Westminster Crucimeter) and IKDC scores. The comparative groups were age and sex matched with a median age of 27 in the ACL reconstruction and meniscectomy group and 27 in the ACL reconstruction and intact meniscus group.

Figures 1 and 2 show the IKDC and Lysholm score distributions. There was a statistically significant difference between mean IKDC scores for meniscal repair, meniscectomy and those patients with normal menisci undergoing ACL reconstruction demonstrated graphically in Fig. 3. Patients had a mean IKDC of 84.2 following meniscal repair at a median follow-up time of 10 years. This compares to a mean score of 70.5 in patients who had

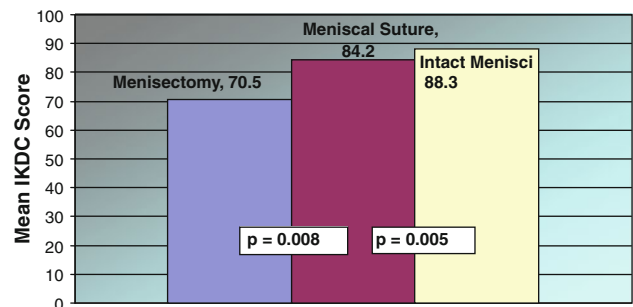


Fig. 3 Comparison of mean IKDC score following meniscectomy, meniscal suture and native menisci, in long-term outcome of ACL reconstruction

undergone meniscectomy and 88.2 in patients with intact menisci. There was no statistically significant difference in scores between the groups when analysed by region of tear. There was no significant difference in the groups when analysed according to whether the patients were operated on at 6–12 weeks post-injury or over 3 months. 86.2% of

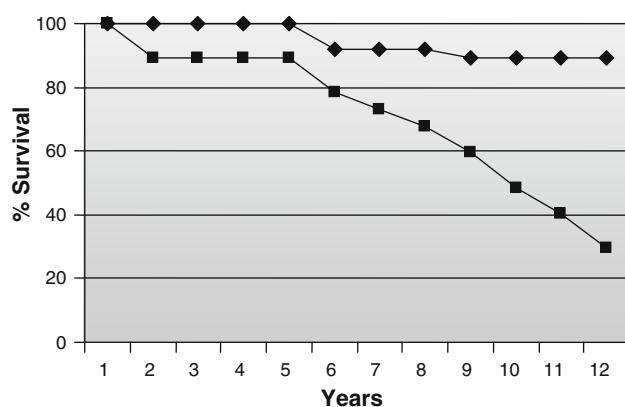


Fig. 4 Best (filled diamond)- and worst (filled square)-case survival curves for meniscal suture with ACLR

patients undergoing ACL reconstruction with combined meniscal repair had Lysholm scores of between 80 and 100%.

Survival analysis by life table method was performed including a worst-case scenario assuming all lost to follow-up as failure at the time of loss. A survival curve (Fig. 4) is included and shows a best case of 89% 10-years survival and at worst a 49% survival.

Discussion

The most important finding of this study is that long-term IKDC scores for patients undergoing ACL reconstruction and meniscal repair remain better than for patients with ACL reconstruction and partial meniscectomy. The study documents the long-term outcome (up to 12.6 years) of inside-out meniscal repair for non-degenerate, non-complex meniscal tears with concurrent ACL reconstruction. Outside-in and all-inside techniques have been used with some success. The outside-in technique can be useful for anterior horn tears, avoids the need for large incisions and the risk of nerve injury, but it is not recommended for posterior horn tears [36]. All-inside techniques have the attraction of smaller incisions and reduced operative time and although good early clinical results have been achieved [2, 11, 22, 41] with healing evident on second-look arthroscopy [3], animal models have demonstrated inferior healing and long-term clinical outcome studies are lacking [17, 27]. The use of a variety of all-inside arthroscopic suture devices, darts, arrows, screws and anchors has been described [10, 15, 18, 20, 45]. The inside-out technique using vertical mattress sutures was used for this study as this has been considered the gold standard to which other techniques have been compared, including series involving elite athletes [23, 27, 44, 46]. Biomechanical testing has also shown that vertical

mattress sutures withstand the greatest forces to failure [5, 47] and that sutures containing ultra high-molecular weight polyethylene provide greater strength than earlier generations of meniscal repair [7].

Traditionally meniscal repair has been confined to the vascular region of the meniscus [8], however, it has been demonstrated that meniscal repair (with a meniscal rim of ≥ 3 mm) is certainly possible and this study demonstrates good long-term survivorship of the repair when undertaken in this zone which is well into the ‘red-white’ zone approaching the ‘white-white’ zone.

The chronicity of injury is believed to influence the potential for meniscal repair with poorer results in cases with significant time lapse following injury. This study did not show this to be significant, nor was there a trend to better function with earlier repair. It may be that different results would have been seen if compared with cases operated on within 3–6 weeks of injury. Current referral patterns in the healthcare system rarely allow operation within 6 weeks. Provided there has not been gross plastic deformation of the meniscus rendering it irreducible, the meniscus may still be repairable in more chronic cases.

This study demonstrates a significant outcome improvement in those ACL reconstruction patients that had meniscal repair compared with partial meniscectomy, with the repair group out performing the meniscectomy group by 14 IKDC points. There was a further significant difference between ACL reconstruction with a repaired meniscus and with intact menisci with the group with intact menisci having better scores. This may be due to a number of factors. It may be attributable to an increased severity of the original injury. An injury which results in ACL rupture and complex meniscal tears requiring meniscectomy may be of higher energy than an injury causing ACL rupture and simple linear tear amenable to surgical repair or without meniscal tear. This disparity of injury severity may lead to differing clinical outcomes because of a primary effect of associated chondral damage or bone bruising on the outcome of the ACL reconstruction regardless of the treatment of concomitant meniscal pathology. The IKDC score will be reduced in the presence of symptoms of pain or instability. The improved scores in meniscal repair compared with meniscectomy may be due to less pain directly attributable to the meniscus itself, less secondary degenerate chondral loss or possibly improved stability due to the secondary restraint that the repaired meniscus provides. The mean IKDC scores were slightly lower following meniscal repair when compared with intact menisci. This may be due to the fact that although the torn meniscus may be repaired, it may not possess the same secondary restraining characteristics of the native meniscus. Five patients had IKDC scores of less than 80%. The average age of these patients was 36, and two patients had both

medial and lateral tears. Three of 5 had tears with a peripheral rim of more than 3 mm.

This study complements the findings of Salmon et al. [37] in whose study there was a significant correlation between meniscectomy and worse long-term outcome following ACL reconstruction. Pernin et al. also found that medial meniscectomy in the context of ACL reconstruction was a major risk factor for the development of osteoarthritis in the long term with almost 25 years follow-up [33]. Aglietti et al. [1] showed that patients with meniscectomy and ACL reconstruction had more pain and degenerate change in the knee compared with meniscal repair and ACL reconstruction. DeHaven et al. [12] also found that symptomatic degenerate change was more prevalent in ACL reconstruction and failed meniscal repair when compared with a group with ACL reconstruction and an intact repair at 10-year follow-up.

When comparing this work to previous studies [38, 39], the authors believe that their selection criteria for meniscal repair may explain the improved subjective IKDC scores in the meniscal repair group. All degenerative or complex tears underwent partial meniscectomy. As discussed above, the severity of injury required to produce a complex tear of the meniscus may also be related to the worse IKDC scores in the meniscectomy group. Johnson, Muellner and Steenbrugge published long-term outcome studies (over 10 years) in patient cohorts undergoing meniscal repair without ACL reconstruction showing clinical success rates of 75% [19], survival of meniscal repair of 91% despite persistent intra-substance high signal on MRI [30] but noted worse results in ACL-deficient knees [42]. Since then, further work has been published confirming improved outcomes of meniscal repair when performed with concomitant ACL reconstruction [15, 21].

Previous works have suggested that site of tear and timing from injury is critical in the survival of meniscal repair. It has been suggested that only red–red and red–white tears of the meniscus are amenable to repair, but this is reliant on early access to surgery, which is not always available in many clinical settings. Medium-term results of ACL reconstruction with meniscectomy or meniscal repair revealed more pain and degeneration in the meniscectomy group at 5 years [1]. Longer-term outcome, however, [39] demonstrated that meniscal repair was not superior from partial meniscectomy, but it was noted that repaired degenerative meniscal tears had lower subjective outcome scores than non-degenerative tears. The authors did not include degenerative tears in this study.

The study was limited by the number of patients involved due to the need to exclude patients with significant chondral damage and those having other secondary procedures at the time of surgery. There was loss to follow-

up as this population is young and geographically mobile. The authors have accounted for this by including best-case and worse-case scenarios.

Conclusion

The authors believe that meniscal repair where possible, in the context of ACL reconstruction, offers the patient the best chance of optimal outcome. This study demonstrates a significant drop in the long-term IKDC score when a partial meniscectomy is performed compared with a repair. Long-term outcome of meniscal repair approaches that of intact menisci in the context of ACL reconstruction. The clinical relevance of these findings is that meniscal repair should be undertaken where possible to improve the long-term outcome for patients with ACL-deficient knees and meniscal tears.

Acknowledgments The authors acknowledge the help received from Dr. J. Ashken (ACL database design), Mrs. S. Waspe, clinical research coordinator at North Hampshire Hospital, Basingstoke (data collection and entry) and Kate Tyson (patient evaluation). This study has been performed in accordance with the ethical standards laid down in the 1964 Declaration of Helsinki. All patients entered into the study through the database understood and agreed to their data being analysed for research purposes.

Conflict of interest The authors declare that they have no conflict of interest.

References

1. Aglietti P, Zacherotti G, De Biase P et al (1994) A comparison between medial meniscus repair, partial meniscectomy, and normal meniscus in anterior cruciate ligament reconstructed knees. *Clin Orthop Relat Res* 307:165–173
2. Ahn JH, Lee YS, Yoo JC, Chang MJ, Koh KH, Kim MH (2010) Clinical and second look arthroscopic evaluation of repaired medial meniscus in anterior cruciate ligament reconstructed knees. *Am J Sports Med* 38:472–477
3. Ahn JH, Wang JH, Yoo JC (2004) Arthroscopic all-inside suture repair of medial meniscus lesion in anterior cruciate ligament deficient knees: results of second-look arthroscopies in 39 cases. *Arthroscopy* 20:936–945
4. Amis A, McDermott I (2006) The consequences of meniscectomy. *J Bone Joint Surg* 88:1549–1556
5. Aros BC, Pedroza A, Vasileff WK, Litsky AS, Flanigan DC (2010) Mechanical comparison of meniscal repair devices with mattress suture devices in vitro. *Knee Surg Sports Traumatol Arthrosc* 18:1594–1598
6. Baratz ME, Fu F, Mengato R (1986) Meniscal tears: the effect of meniscectomy and of repair on the intra-articular contact areas and stresses in the human knee. *Am J Sports Med* 14:270–275
7. Barber FA, Herbert MA, Schroeder FA, Aziz-Jacobo J, Sutker MJ (2009) Biomechanical testing of new meniscal repair techniques containing ultra high-molecular weight polyethylene suture. *Arthroscopy* 25:959–967

8. Beaufils P, Hulet C, Dhenain M, Nizard R, Nourissat G, Pujol N (2009) Clinical practice guidelines for the management of meniscal lesions and isolated lesions of the anterior cruciate ligament of the knee in adults. *Rev Chir Orthop Traumatol* 95:437–442
9. Boyd KT, Myers PT (2003) Meniscus preservation; rationale, repair techniques and results. *Knee* 10:1–11
10. Bryant D, Dill J, Litchfield R, Amendola A, Giffin R, Fowler P, Kirkley A (2007) Effectiveness of bioabsorbable arrows compared with inside-out suturing for vertical, reparable meniscal lesions: a randomized clinical trial. *Am J Sports Med* 35:889–896
11. Choi NH, Kim TH, Victoroff BN (2009) Comparison of arthroscopic medial meniscal suture repair techniques: inside-out versus all-inside repair. *Am J Sports Med* 37:2144–2150
12. DeHaven KE, Lohrer WA, Lovelock JE (1995) Long-term results of open meniscal repair. *Am J Sports Med* 23:524–530
13. Fairbank TJ (1948) Knee joint changes after meniscectomy. *J Bone Joint Surg Br* 30:640–664
14. Feng H, Hong L, Geng XS et al (2008) Second-look arthroscopic evaluation of bucket-handle meniscus tears repairs with anterior cruciate ligament reconstruction: sixty-seven consecutive cases. *Arthroscopy* 24:1358–1366
15. Haas AL, Schepisis AA, Hornstein J, Edgar CM (2005) Meniscal repair using the FasT-Fix all-inside meniscal repair device. *Arthroscopy* 21:167–175
16. Hefti F, Muller W, Jakob RP, Staubli HU (1993) Evaluation of knee ligament injuries with the IKDC form. *Knee Surg Sports Traumatol Arthrosc* 1:226–234
17. Hospodar SJ, Schmitz MR, Golish SR, Ruder CR, Millar MD (2009) FasT-Fix versus inside-out suture meniscal repair in the goat model. *Am J Sports Med* 37:330–333
18. Jarvela S, Sihvonen R, Sirkeoja H, Jarvela T (2010) All-inside meniscal repair with bioabsorbable meniscal screws or with bioabsorbable meniscus arrows: a prospective, randomised clinical study with 2-year results. *Am J Sports Med* 38:2211–2217
19. Johnson MJ, Lucas GL, Dusek JK, Henning CE (1999) Isolated arthroscopic meniscal tear: a long-term outcome study (more than 10 years). *Am J Sports Med* 27:44–49
20. Kalliakmanis A, Zourntos S, Bousgas D, Nikolaou P (2008) Comparison of arthroscopic meniscal repair results using 3 different meniscal repair devices in anterior cruciate ligament reconstruction patients. *Arthroscopy* 24:810–816
21. Kim HJ, Rodeo SA (2003) Approach to meniscal tears in anterior cruciate ligament reconstruction. *Orthop Clin North Am* 34:139–147
22. Konan S, Haddad FS (2010) Outcomes of meniscal preservation using all-inside meniscus repair techniques. *Clin Orthop Relat Res* 468:1209–1213
23. Logan M, Watts M, Owen J, Myers P (2009) Meniscal repair in the elite athlete: results of 45 repairs with a minimum 5-year follow up. *Am J Sports Med* 37:1131–1134
24. Lohmander LS, Englund PM, Dahl LL, Roos EM (2007) The long-term consequence of anterior cruciate ligament and meniscus injuries: osteoarthritis. *Am J Sports Med* 35:1756–1769
25. Lubowitz JH, Verdonk PC, Reid JB, Verdonk R (2007) Meniscus allograft transplantation: a current concepts review. *Knee Surg Sports Traumatol Arthrosc* 15:476–492
26. Macnicol MF, Thomas NP (2000) The knee after meniscectomy. *J Bone Joint Surg Br* 82:157–159
27. McCarty EC, Marx RG, DeHaven KE (2002) Meniscus repair: considerations in treatment and update of clinical results. *Clin Orthop Relat Res* 402:122–134
28. McDermott I, Thomas NP (2006) Human meniscal allograft transplantation. *Knee* 13:69–71
29. McGinty JB, Guess LF, Marvin RA (1977) Partial or total meniscectomy: a comparative analysis. *J Bone Joint Surg Am* 59:763–766
30. Muellner T, Egkher A, Nikolic A, Funovics M, Metz V (1999) Open meniscal repair: clinical and magnetic resonance imaging findings after 12 years. *Am J Sports Med* 27:16–20
31. Neyret P, Walch G, Dejour H (1988) Intramural internal meniscectomy using the trillat technic. Long-term results of 258 operations. *Rev Chir Orthop Reparat Appar Mot* 74:637–646
32. Northmore-Ball MD, Dandy DJ, Jackson RW (1983) Arthroscopic, open partial and total meniscectomy. A comparative study. *J Bone Joint Surg Br* 65:400–404
33. Pernin J, Verdonk P, Si Selmi TA, Massin P, Neyret P (2010) Longterm follow-up of 24.5 years after intra-articular anterior cruciate ligament reconstruction with lateral extra-articular augmentation. *Am J Sports Med* 38:1094–1102
34. Pujol N, Beaufils P (2009) Healing results of meniscal tears left in situ during anterior cruciate ligament reconstruction: a review of clinical studies. *Knee Surg Sports Traumatol Arthrosc* 17:396–401
35. Rangger C, Klestil T, Gloetzer W, Kemmler G, Benedetto KP (1995) Osteoarthritis after arthroscopic partial meniscectomy. *Am J Sports Med* 23:240–244
36. Rodeo S (2000) Arthroscopic meniscal repair with use of the outside-in technique. *Instr Course Lect* 49:195–206
37. Salmon LJ, Russell VJ, Refshauge K, Kader D, Connolly C, Linklater J, Pinczewski LA (2006) Long-term outcome of endoscopic anterior cruciate ligament reconstruction with patellar tendon autograft. *Am J Sports Med* 34:721–732
38. Shelbourne KD, Rask BP (2001) The sequelae of salvaged non-degenerative peripheral vertical medial meniscus tears with anterior cruciate ligament reconstruction. *Arthroscopy* 17:270–274
39. Shelbourne KD, Carr DR (2003) Meniscal repair compared with meniscectomy for bucket-handle medial meniscal tears in anterior cruciate ligament: reconstructed knees. *Am J Sports Med* 31:718–723
40. Simpson DA, Thomas NP, Aichroth PM (1986) Open and closed meniscectomy. A comparative analysis. *J Bone Joint Surg Br* 68:301–304
41. Starke C, Kopf S, Peteren W, Becker R (2009) Meniscal repair. *Arthroscopy* 25:1033–1044
42. Steenbrugge F, Verdonk R, Verstraete K (2002) Longterm assessment of arthroscopic meniscus repair: a 13 year follow-up study. *Knee* 9:181–187
43. Stein T, Mehling AP, Welsch F, Von Eisenhart-Rothe R, Jager A (2010) Long-term outcome after arthroscopic meniscal repair versus arthroscopic partial meniscectomy for traumatic meniscal tears. *Am J Sports Med* 38:1542–1548
44. Tengroetenhuysen M, Meermans G, Pittoors K, Van Riet R, Victor J (2011) Longterm outcome after meniscal repair. *Knee Surg Sports Traumatol Arthrosc* 19:236–241
45. Tsai AM, McAllister DR, Chow S, Young CR, Hame SL (2004) Results of meniscal repair using a bioabsorbable screw. *Arthroscopy* 20:586–590
46. Turman KA, Diduch DR (2008) Meniscal repair: indications and techniques. *J Knee Surg* 21:154–162
47. Walsh SP, Evans SL, O'Doherty DM, Barlow IW (2001) Failure strengths of suture vs biodegradable arrow and staple for meniscal repair: an in vitro study. *Knee* 8:151–156