

Reconstruction of the Posterior Oblique Ligament and the Posterior Cruciate Ligament in Knees With Posteromedial Instability

Andre Weimann, M.D., Imke Schatka, M.D., Mirco Herbort, M.D., Andrea Achtnich, M.D.,
Thore Zantop, M.D., Ph.D., Michael Raschke, M.D., and Wolf Petersen, M.D., Ph.D.

Purpose: Posterior cruciate ligament (PCL) injuries are often associated with injuries of the posteromedial structures of the knee. The motivation for this study was the attempt to test different reconstruction techniques for the structures of the posteromedial corner in a biomechanical experiment. **Methods:** Kinematic studies were carried out on 10 cadaveric knees exposed to a 134-N posterior tibial load, 10-Nm valgus torque, and 5-Nm internal torque at 0°, 30°, 60°, and 90° of flexion. The resulting posterior tibial translation (PTT) was determined using a robotic/universal force-moment sensor testing system for (1) intact knees, (2) PCL-deficient knees, (3) knees with deficiency of the PCL and the posteromedial structures, (4) knees with only the PCL reconstructed, (5) knees with the PCL and posterior oblique ligament (POL) reconstructed, and (6) knees with the PCL, medial collateral ligament (MCL), and POL reconstructed. Kinematic data were analyzed by a 2-factor repeated analysis of variance. **Results:** When both the PCL and the posteromedial structures were cut, PTT increased significantly at all flexion grades under a posterior tibial load ($P < .05$). Reconstruction of only the PCL could not restore PTT at 0°, 30°, 60°, and 90° of flexion under loading conditions in a knee with combined injury of the PCL and the posteromedial structures ($P > .05$). Additional reconstruction of the POL improved PTT at all flexion angles in comparison with only the PCL-reconstructed knee. Reconstruction of the MCL had no significant effect on PTT. **Conclusions:** This study shows that reconstruction of the POL contributes significantly to the normalization of coupled PTT in knees with combined injury of the PCL and the posteromedial structures under valgus or internal rotational moment. The supplementary reconstruction of the MCL did not provide significant improvement in knee kinematics. **Clinical Relevance:** The POL should be addressed in the patient with combined injuries of the PCL and the posteromedial structures.

Some clinical studies have reported unfavorable clinical outcomes after isolated posterior cruciate ligament (PCL) reconstruction at midterm follow-up

in a large number of patients.^{1,2} One explanation for the high incidence of fair to poor clinical results in treating PCL-injured patients may be the high incidence of unrecognized or inadequately treated associated injuries. Studies have shown that a high percentage of PCL injuries are combined with injury to other structures in the knee.^{1,3-5}

Lesions of the posterolateral structures are the most frequently associated injuries, being seen in 60% of patients with PCL injuries.^{1,3-5} Biomechanical studies show that a graft that restores knee kinematics for an isolated PCL may be overloaded and will fail if the posterolateral structures are also deficient and not addressed surgically.⁶⁻¹⁰ Therefore surgical repair and/or reconstruction of the posterolateral corner and

From the Department of Trauma-, Hand- and Reconstructive Surgery, Westfalian Wilhelms University (A.W., I.S., M.H., T.Z., M.R.), Münster, Germany; and Department of Traumasurgery, Martin-Luther-Hospital (A.A., W.P.), Berlin, Germany.

The authors report that they have no conflicts of interest in the authorship and publication of this article.

Received December 9, 2010; accepted February 2, 2012.

Address correspondence to Wolf Petersen, M.D., Ph.D., Klinik für Orthopädie und Unfallchirurgie, Martin Luther Krankenhaus, Caspar Theys Strasse 27-31, 14193, Berlin, Germany. E-mail: w.petersen@mlk-berlin.de

© 2012 by the Arthroscopy Association of North America
0749-8063/10739/\$36.00

doi:10.1016/j.arthro.2012.02.003

the PCL is recommended in the presence of combined injury both in the acute setting and with chronic instability.³⁻⁵

In recent years, with the emphasis on the posterolateral structures, less attention has been paid to the posteromedial structures. However, especially after high-velocity trauma, a high prevalence of associated posteromedial injuries is reported.^{3,4} A recent review article has shown that in the multiligamentous-injured knee, untreated posteromedial instability can be considered a cause for failure of a PCL reconstruction.¹¹

Four principal structural elements can be found in the posteromedial corner: the superficial medial collateral ligament (sMCL), the deep medial collateral ligament (dMCL), the posterior oblique ligament (POL), and the posteromedial capsule (PMC).¹²⁻¹⁵ A recent biomechanical study has shown that the POL is an important restraint to posterior tibial translation (PTT) in the PCL-deficient knee.¹² These data support the clinical theory that untreated injuries to the POL may contribute to PCL graft failure. In patients with combined injuries, instability may be pronounced because the functional deficiency of 1 ligament may affect the healing of the others.

The treatment of posteromedial instabilities is still controversial. Surgical procedures generally consisted of repair or reattachment of the capsular structures including the posteromedial component.^{3,4,14,15} Mueller¹⁶ recommended reconstructing the POL in patients with posteromedial instabilities with an autologous graft of the semimembranosus tendon. Other medial reconstruction techniques replace both the POL and the medial collateral ligament (MCL)¹² or only the MCL.¹⁷

The motivation for this study was the attempt to test different reconstruction techniques for the structures of the posteromedial corner in a biomechanical experiment. Our hypothesis was that the combined reconstruction of the POL and PCL would be more effective than isolated PCL reconstruction in restoring knee kinematics.

METHODS

Material

The study used 10 fresh-frozen human cadaveric knees (6 male and 4 female specimens; age range, 55 to 78 years; mean age, 72 years). The knees were obtained from body donors in the department of anatomy. All knees were inspected carefully for scars indicating previous arthroscopic or open surgery. Af-




FIGURE 1. UFS/robotic testing system. The tibia was mounted to the UFS, which is connected to the robot. The femur was mounted to the base of the robot. Three different forces were applied: 134-N posterior load, 10-Nm valgus torque, and 5-Nm internal torque.

ter arthrotomy, the joint was inspected for arthritic changes. Previous surgery or arthritic changes were exclusion criteria.

For the different reconstructions, human hamstring tendons were used. The grafts were harvested from body donors with a stripping device. Immediately after harvesting, the grafts were stored at -20°C . Before testing, all tendons were thawed at room temperature for 12 hours and kept moist with saline solution irrigation during preparation to prevent dehydration. Before testing, the knees were stored at -20°C and thawed for 12 hours at room temperature.

Testing Protocol Using Robotic/Universal Force-Moment Sensor Testing System

The femur and the tibia were cut 20 cm from the joint line and mounted in aluminum cylinders with polymethyl methacrylate bone cement (Palacos; Merck, Darmstadt, Germany). The tibial side of this construct was connected to a universal force-moment sensor (UFS) (FTI Theta 1500-240; Schunk, Lauffen, Germany) that was firmly fixed to the end effector of a 6-*df* robotic manipulator (KR 125; KUKA Robots, Augsburg, Germany). The femoral cylinder was mounted to the base of the robot (Fig 1).

At the beginning, the path of passive flexion-extension of the intact knee joint was determined by the robotic/UFS testing system. This was achieved by maintaining a target force and moment of 0 in all remaining degrees of freedom. The robotic/UFS testing system found the positions of the knee that minimized all external forces and moments applied to the joint throughout the range of flexion from 0° to 90° in

increments of 1° . These positions served as the starting point for application of a 134-N posterior tibial load, 10-Nm valgus torque, and 5-Nm internal torque at 0° , 30° , 60° , and 90° of knee flexion. The 3 loading conditions were tested separately.

The external loads were reapplied to the knee after sequential cutting of the PCL and then after cutting of the posteromedial corner (MCL, POL, and PMC), after single-bundle PCL reconstruction, after additional reconstruction of the POL, and finally, after reconstruction of the MCL, POL, and PMC. The resulting kinematics for PTT, valgus torque, and internal torque were recorded by the testing system.

The system is capable of highly accurate kinematic measurements, such as anteroposterior translation, medial-lateral translation, proximal-distal translation, varus-valgus rotation, and internal-external rotation of joint motion.¹⁸ By use of the principle of superimposition, the apparatus allows calculation of constraining force attributed to the graft or the PCL at various angles of knee flexion. The repeatability of this system is 0.2 mm and 0.02° for orientation and position of the end effector, respectively.¹⁹ The robotic manipulator is capable of achieving positional control of the knee in 6 *df*, whereas the UFS can measure 3 orthogonal forces and moments. Simultaneously, this system is capable of operating in a force-controlled mode through the force feedback from the UFS to the robot.

PCL Reconstruction Technique

PCL reconstruction was performed through a small anterolateral arthrotomy. A semitendinosus gracilis 4-stranded graft with a length of 12 cm was prepared on a standard preparation board. A bone tunnel according to the diameter of the graft (9 or 10 mm) was drilled in the femoral insertion of the anterolateral bundle by use of a specific drill guide (femoral PCL guide; Karl Storz, Tuttlingen, Germany), and a second bone tunnel was drilled through the tibia, ending in the center of the tibial insertion of the PCL. For tibial tunnel placement, an additional posterior approach was made and a specific drill guide (PCL guide; Karl Storz) was used.

A hybrid technique with a button and interference screw was used for femoral and tibial fixation (Flip tack, Endo tack, and MegaFix interference screw; Karl Storz). The screw diameter was chosen according to the tunnel diameter. Tensioning was performed after multiple cycling of the knee in 90° of flexion with a load of 80 N with a tensiometer.

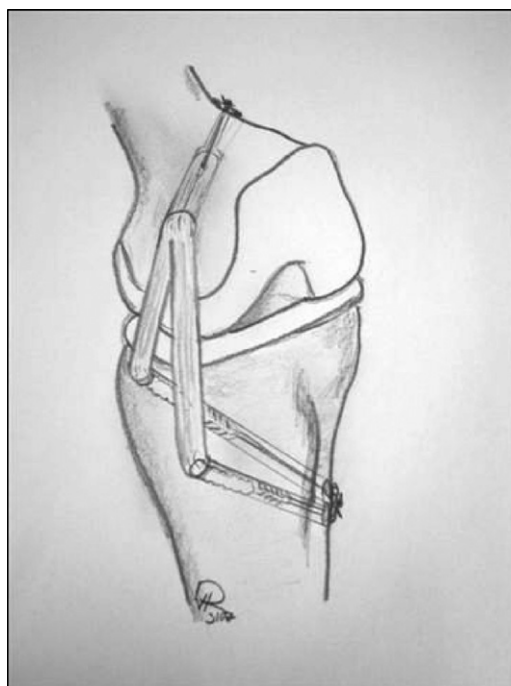


FIGURE 2. Reconstruction of the MCL and POL with double-stranded semitendinosus graft.

Reconstruction Technique of Posteromedial Structures

A semitendinosus graft was used to reconstruct both the MCL and the POL (Fig 2). The tendon was looped, and a flip button (Flip tack; Karl Storz) was placed within the proximal loop. One strand of the graft should replace the MCL (sMCL and dMCL), and the other strand should replace the POL. A double loop of 1 mm of polyethylene suture material was used to connect tendon loop and button. No. 2 polyethylene suture material was used for the preparation of the strands.

The common femoral tunnel was placed at the medial epicondyle with a diameter of 8 mm. The tibial tunnel (diameter of 6 mm) for the MCL was placed in the anteromedial aspect of the tibia approximately 6 cm below the joint line at the distal insertion of the MCL. The tibial tunnel for the POL (diameter of 6 mm) was placed in the posteromedial aspect of the tibial plateau approximately 1.5 cm below the joint line just proximal to the insertion of the semimembranosus muscle. This area represents the insertion of the POL. To ensure that the tunnels' exits do not intersect, drilling was performed with K-wires by use of an anterior cruciate ligament (ACL) aimer to guide the

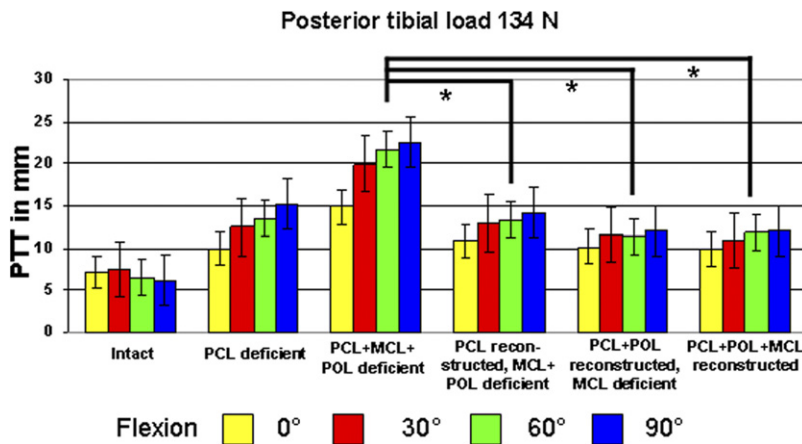


FIGURE 3. PTT in response to posterior tibial load of 134 N (mean \pm standard deviation). Asterisks, statistically significant results ($P < .05$).

drill direction. There was a small bony bridge between both tunnels (5 mm) over which the holding sutures of both tendon strands were connected.

The loop of the graft was pulled into the femoral tunnel, the button was flipped, and manual tension was applied to the graft. The anterior strand of the graft was then pulled through the anterior tibial tunnel, and the posterior strand was pulled through the posterior tibial tunnel.

The anterior strand of the graft was tensioned manually at full extension and fixated with a biodegradable interference screw (6-mm-diameter MegaFix). The POL graft was tensioned at 45° of flexion in the same fashion.

Statistical Analysis

All knee conditions (intact, all ligaments deficient, and reconstructed) were tested in every specimen. Because each specimen was tested in the intact state and then after sequential sectioning of the PCL, MCL, POL, and PMC and the reconstruction of all ligaments, the kinematic data for each state were analyzed by a 2-factor repeated analysis of variance. The 2 factors evaluated were the condition of the knee (intact, transected, and reconstructed) and the different knee flexion angles. The dependent variables evaluated were knee kinematics. Significance was set at $P < .05$.

RESULTS

PTT at 134-N Posterior Load

Under the 134-N posterior tibial load, PTT of the intact knee varied from a mean of 7.35 ± 2.57 mm at full extension to 6.97 ± 2.33 mm at 90° of flexion

(Fig 3). After the PCL was sectioned, these translations increased significantly to 10.02 ± 2.39 mm at 0° of flexion, 12.56 ± 4.21 mm at 30°, 13.97 ± 2.10 mm at 60°, and 15.98 ± 2.87 mm at 90° ($P < .05$). In comparison with the PCL-deficient knee, PTT significantly increased after additional sectioning of the MCL, POL, and PMC (15.06 ± 2.19 mm at 0°, 11.45 ± 2.47 mm at 30°, 13.78 ± 2.5 mm at 60°, and 15.46 ± 2.3 mm at 90°).

PCL reconstruction improved PTT at every flexion angle significantly (8.86 ± 2.17 mm at 0°, 20.32 ± 3.59 mm at 30°, 22.88 ± 2.02 mm at 60°, and 23.96 ± 3.23 mm at 90°). Reconstruction of the POL further improved PTT significantly in comparison with the PCL-, POL-, and MCL-deficient knee at all flexion angles ($P < .05$) (10.87 ± 2.38 mm at 0°, 12.89 ± 3.65 mm at 30°, 12.29 ± 2.66 mm at 60°, and 13.12 ± 4.21 mm at 90°; $P > .05$). After additional reconstruction of the MCL, PTT did not decrease significantly (9.97 ± 2.65 mm at 0°, 11.98 ± 4.45 mm at 30°, 12.41 ± 2.86 mm at 60°, and 13.03 ± 4.67 mm at 90°; $P > .05$) in comparison with the PCL- and POL-reconstructed knee.

PTT at 10-Nm Valgus Torque

Under the load of 10-Nm valgus torque, PTT varied between 1.53 ± 0.9 mm at 0° and 3.89 ± 2.31 mm at 90° of knee flexion, with a significant difference among the values at the 4 tested positions in the intact knee (Fig 4). At higher degrees of flexion, there was an increase in PTT throughout the whole series. After the PCL was sectioned, PTT only slightly increased, to 1.86 ± 1.07 mm at 0°, to 3.26 ± 1.7 mm at 30°, to 4.22 ± 2.22 mm at 60°, and to 5.73 ± 2.36 mm at 90°. Further sectioning of the posteromedial structures increased PTT at all flexion angles significantly in comparison with the PCL-

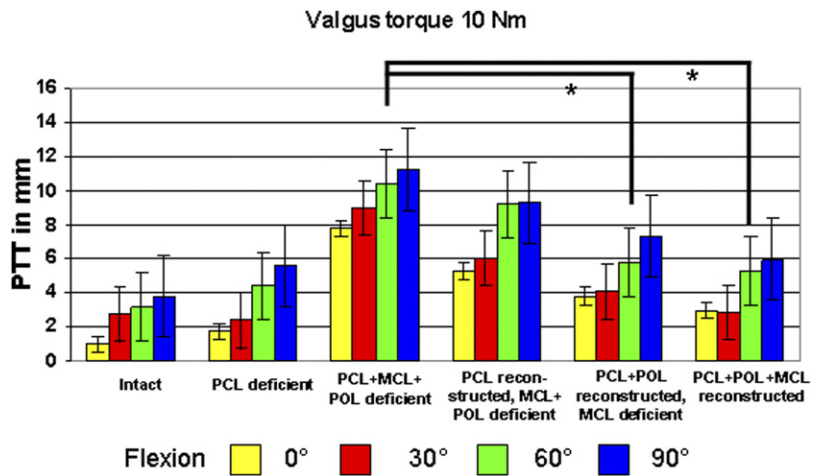


FIGURE 4. PTT in response to 10-Nm valgus torque (mean ± standard deviation). Asterisks, statistically significant results ($P < .05$).

deficient knee (8.09 ± 0.83 mm at 0° , 9.09 ± 1.84 mm at 30° , 10.15 ± 2.16 mm at 60° , and 11.29 ± 2.07 mm at 90° ; $P < .05$).

Reconstruction of the PCL only resulted in no significant improvement of the PTT in comparison with the PCL-/POL-/MCL-deficient knee especially at higher flexion angles (5.69 ± 0.68 mm at 0° , 5.99 ± 1.84 mm at 30° , 9.15 ± 2.1 mm at 60° , and 9.22 ± 2.27 mm at 90°).

When the PCL and the POL were reconstructed, PTT improved significantly in comparison with the single PCL reconstruction (3.89 ± 0.63 mm at 0° , 4.09 ± 1.8 mm at 30° , 5.95 ± 1.96 mm at 60° , and 7.67 ± 2.47 mm at 90° ; $P < .05$). Additional reconstruction of the MCL did not decrease PTT significantly in comparison with the PCL/POL reconstruction.

PTT at 5-Nm Internal Torque

Under the load of 5-Nm internal rotation, PTT varied between 6.83 ± 2.1 mm at 0° and 4.89 ± 1.36 mm at 90° of knee flexion, with no significant differences among the values at the 4 tested positions in the intact knee (Fig 5). After the PCL was sectioned, PTT increased significantly to 9.56 ± 2.77 mm at 0° , 11.41 ± 3.87 mm at 30° , 12.72 ± 2.2 mm at 60° , and 14.23 ± 3.56 mm at 90° ($P < .05$). Further sectioning of the posteromedial structures increased PTT at all flexion angles in comparison with the PCL-deficient knee (15.09 ± 2.83 mm at 0° , 19.99 ± 3.04 mm at 30° , 22.95 ± 2.16 mm at 60° , and 23.22 ± 3.27 mm at 90° ; $P < .05$).

Reconstruction of only the PCL resulted in significant improvement of the PTT at all flexion angles in comparison with the PCL-/POL-/MCL-deficient knee ($12.69 \pm$

FIGURE 5. PTT in response to 5-Nm internal torque (mean ± standard deviation). Asterisks, statistically significant results ($P < .05$).

2.83 mm at 0°, 13.89 ± 3.54 mm at 30°, 14.15 ± 2.76 mm at 60°, and 14.02 ± 3.87 mm at 90°; $P < .05$).

When the PCL and the POL were reconstructed, PTT improved in comparison with the isolated PCL reconstruction (9.69 ± 2.23 mm at 0°, 8.79 ± 3.04 mm at 30°, 7.85 ± 2.76 mm at 60°, and 8.02 ± 4.27 mm at 90°; $P < .05$). Additional reconstruction of the MCL did not further improve PTT and showed the same results at the 4 tested positions.

DISCUSSION

The biomechanical results confirm our hypothesis that reconstruction of the POL with a tendon graft improves PTT in the PCL-reconstructed knee. The supplementary reconstruction of the MCL did not provide significant improvement in knee kinematics. These data support the clinical theory that the POL should be replaced by a tendon graft in combined injuries of the posteromedial corner and the PCL.^{15,17}

The results of our study support previous findings that the POL has a distinct role in controlling PTT in the PCL-deficient knee.¹² In a sequential-cutting study using a UFS robotic testing system, it has been shown that the POL is a restraint to PTT when the knee is flexed.¹² Robinson et al.²⁰ found that the PMC (including the POL) is an important structure for controlling PTT in the PCL-intact knee. Anatomic studies have shown that internal rotation tightens the PMC.^{13,19} This finding explains the stabilizing role of the POL graft under tibial internal rotation.

It is important to note that in this study, we simulated an injury to posteromedial structures by sectioning all structures of the posteromedial corner. Previous studies have found that with sectioning merely 1 component of the posteromedial corner (e.g., MCL, POL, or posterior capsule), the changes in knee kinematics would be significantly less than with sectioning 2 or more components.¹² Hence our data do represent a worst-case scenario. In the clinical situation a careful diagnostic evaluation is needed to decide which patient would profit from an additional POL reconstruction.

Whereas the role of the posteromedial structures for the stabilization of the knee joint seems to be understood, there is only little agreement on how to manage patients with chronic posteromedial instability.²¹ To our knowledge, this is the first biomechanical cadaveric study about a reconstruction technique for posteromedial instability. This study showed the importance of reconstructing the POL in patients with combined injury of the PCL and the posteromedial structures. The technique presented cannot be trans-

ferred to the clinic because there are several questions that are still unanswered. First, the technique for fixation of the POL graft has been adopted from techniques used for ACL reconstruction, and we have used this technique successfully in a limited number of patients. Second, the ideal graft material for POL replacement has not been identified so far. Harvesting of autologous grafts on the ipsilateral side in this procedure may result in a loss of function of the pes tendons as secondary medial stabilizers. Third, it is not known how the graft should be tensioned. To answer all these questions, further research is needed.

It must be noted that even after the combined reconstruction of the PCL and POL, a notable amount of PTT still exists. A potential problem with the presented surgical procedure is its inability to reproduce the shape of the large and flat femoral origin and tibial insertion of the POL.^{13,16,20}

In the literature there are only a few reports about reconstructions of the medial and posteromedial structures. Yoshiya et al.¹⁷ reported a surgical procedure using autogenous semitendinosus and gracilis tendons to anatomically reconstruct the anterior longitudinal component of the sMCL. As in our study, the tendon grafts were fixated with interference screws. These authors treated 27 patients with symptomatic medial instability with this surgical procedure. At follow-up, medial stability, as well as postoperative range of motion, was graded as normal or nearly normal in all patients. In accordance with the biomechanical findings of our study, the authors concluded that a potential problem with this procedure was that only the anterior longitudinal part of the sMCL was reconstructed. They further stated that especially in the combined ligament-injured knees, instability against rotatory stress is thought to remain to some extent, even after the reconstruction of the anterior longitudinal MCL.

Fanelli and Harris¹⁵ described a surgical procedure where an allograft is secured to the anatomic insertion sites of the sMCL using screws and spiked ligament washers. The PMC is secured to the allograft tissue to eliminate posteromedial capsular laxity. Another study²² presents the 2-year follow-up results of 15 arthroscopic-assisted ACL-PCL reconstructions. This study group consisted of 4 ACL-PCL-MCL injuries and 5 ACL-PCL-posterolateral corner-MCL injuries. Medial-side injuries were treated surgically by primary repair, posteromedial capsular shift, and allograft augmentation as indicated. Post-reconstruction physical examination results of the medial-side treatment showed that 30° and 0° valgus stress testing was restored to normal in all 9 knees with medial-side laxity. Although these results

underline the importance of reconstructing the PMC, the absolute number of cases is too small to draw definite conclusions.

One limitation of our study is that the important influence of the muscles is not taken into consideration. In vivo, muscle activities have a great influence on the kinematics of the knee. The posterior medial corner is augmented by the semimembranosus tendons just below the joint line.^{19,20} It has various extensions into the posterior capsule.¹⁹ In deep flexion the semimembranosus muscle tendon tenses the tendon sheath.¹⁹ However, the tendon's tension acts approximately parallel to the femur, and it pulls the PMC proximally when the knee is at low flexion angles. The proximal part of the capsule that crosses the joint line is therefore kept slack by this tendon's action, and so it is then unlikely to stabilize the knee.¹⁹ The semimembranosus tendon inserts at the tibial plateau and tends to pull the tibia posterior, thus increasing PTT. The proximal part of the PMC is the origin of the medial gastrocnemius muscle.¹³ This muscle could theoretically be able to tense the proximal PMC when the knee is flexed. A further research direction is therefore to evaluate the role of the MCL and POL tendon grafts under simulated muscle load and in the in vivo situation. However, our anatomic studies have shown that the POL has no connection to any muscle; therefore this structure must be considered an important passive stabilizer against PTT.

Another limitation of our study is the fact that injuries of the posteromedial structures are often associated with ACL tears.⁴ That condition was not tested in our kinematic study and needs to be clarified in further research.

CONCLUSIONS

This study shows that a reconstruction of the POL contributes significantly to the normalization of coupled PTT in knees with combined injury of the PCL and the posteromedial structures under valgus or internal rotational moment. The supplementary reconstruction of the MCL did not provide significant improvement in knee kinematics.

REFERENCES

1. Harner CD, Waltrip RL, Bennett CH, Francis KA, Cole B, Irrgang JJ. Surgical management of knee dislocations. *J Bone Joint Surg Am* 2004;86:262-273.
2. Meyer H. Die Mechanik des Kniegelenkes. *Arch Anat Physiol Wiss Med* 1853:497547.
3. Fanelli GC, Giannotti BF, Edson CJ. Arthroscopically assisted combined posterior cruciate ligament/posterior lateral complex reconstruction. *Arthroscopy* 1996;12:521-530.
4. Fanelli GC. Combined ACL/PCL/medial/lateral side injuries. In: Fanelli GC, ed. *The multiple ligament injured knee joint*. Chapter 8. New York: Springer, 2004;111-132.
5. Margheritini F, Rihn J, Musahl V, Mariani PP, Harner C. Posterior cruciate ligament injuries in the athlete: An anatomic, biomechanical and clinical review. *Sports Med* 2002;32:393-408.
6. Harner CD, Vogrin TM, Höher J, Ma CB, Woo SL. Biomechanical analysis of a posterior cruciate ligament reconstruction. Deficiency of the posterolateral structures as a cause of graft failure. *Am J Sports Med* 2000;28:32-39.
7. Höher J, Harner CD, Vogrin TM, Baek GH, Carlin GJ, Woo SL. In situ forces in the posterolateral structures of the knee under posterior tibial loading in the intact and posterior cruciate ligament-deficient knee. *J Orthop Res* 1998;16:675-681.
8. Nicholas JA. The five-one reconstruction for anteromedial instability of the knee. Indications, technique, and the results in fifty-two patients. *J Bone Joint Surg Am* 1973;55:899-922.
9. O'Donoghue DM. Reconstruction for medial instability of the knee: Technique and results in sixty cases. *J Bone Joint Surg Am* 1973;55:941-955.
10. Slocum DB, Larson RL, James SL. Late reconstruction of ligamentous injuries of the medial compartment of the knee. *Clin Orthop Relat Res* 1974;23-55.
11. Hammoud S, Reinhardt KR, Marx RG. Outcomes of posterior cruciate ligament treatment: A review of the evidence. *Sports Med Arthrosc* 2010;18:280-291.
12. Petersen W, Loerch S, Schanz S, Raschke M, Zantop T. The role of the posterior oblique ligament in controlling posterior tibial translation in the posterior cruciate ligament-deficient knee. *Am J Sports Med* 2008;36:495-501.
13. Robinson JR, Bull AMJ, Amis AA. Structural properties of the medial collateral ligament complex of the human knee. *J Biomech* 2005;38:1067-1074.
14. LaPrade RF, Morgan PM, Wentorf FA, Johansen S, Engebretsen L. The anatomy of the posterior aspect of the knee. An anatomic study. *J Bone Joint Surg Am* 2007;89:758-764.
15. Fanelli GC, Harris JD. Surgical treatment of acute medial collateral ligament and posteromedial corner injuries of the knee. *Sports Med Arthrosc Rev* 2006;14:78-83.
16. Mueller W. *The knee. Form, function, and ligament reconstruction*. Berlin: Springer, 1983.
17. Yoshiya S, Kuroda R, Mizuno K, Yamamoto T, Kurosaka M. Medial collateral ligament reconstruction using autogenous hamstring tendons: Technique and results in initial cases. *Am J Sports Med* 2005;33:1380-1385.
18. Lemburg T. A robotic/UFS test system for the evaluation of knee kinematics. Degree for engineering sciences. Germany: Advanced technical college Heide, Schleswig Holstein, 2004.
19. Amis AA, Bull AMJ, Gupte CM, Hijazi I, Race A, Robinson JR. Biomechanics of the PCL and related structures: Posterolateral, posteromedial and meniscofemoral ligaments. *Knee Surg Sports Traumatol Arthrosc* 2003;11:271-281.
20. Robinson JR, Sanchez-Ballester J, Bull AMJ, Thomas RdWM, Amis AA. The posteromedial corner revisited. An anatomical description of the passive restraining structures of the medial aspect of the human knee. *J Bone Joint Surg Br* 2004;86:674-681.
21. Lind M, Jakobsen BW, Lund B, Hansen MS, Abdallah O, Christiansen SE. Anatomical reconstruction of the medial collateral ligament and posteromedial corner of the knee in patients with chronic medial collateral ligament instability. *Am J Sports Med* 2009;37:1116-1122.
22. Fanelli GC, Edson CJ, Orcutt DR, Harris JD, Zijerdi D. Treatment of combined anterior cruciate-posterior cruciate ligament-medial-lateral side knee injuries. *J Knee Surg* 2005;18:240-248.